

Analysis of Human Remains from Guana Island, BVI

By:

Shannon S. Mahoney

Autumn Barrett

Mark Kostro

Michael L. Blakey

22 September 2005

Report No. 4, Institute for Historical Biology, Department of
Anthropology, College of William and Mary, Williamsburg,
Virginia, USA

Analysis of Human Remains from Guana Island, BVI

Submitted By:
Michael L. Blakey, Director
Institute for Historical Biology
Department of Anthropology
College of William and Mary
Williamsburg, Virginia
USA

To:
Dr. Henry Jarecki
Mrs. Gloria Jarecki
Guana Island Hotel Corporation &
The Falconwood Corporation

and

Dr. Marley Brown III, Director of Archaeology
Colonial Williamsburg Foundation
Williamsburg, Virginia
USA

Table of Contents

Section	Pages
I. Introduction	1
II. Historical Background	2
British Virgin Islands	2
Guana	3
III. Environmental and Archaeological Background	6
Surrounding Environment	6
Archaeological Site Context	8
IV. Inventory (In-Field and Lab) and Condition of Remains	10
V. Laboratory Methodology	12
VI. Demographic Information	14
Burial 1	14
Burial 2	23
VII. Pathology	27
Burial 1	27
Burial 2	43
VIII. Biographical Interpretation	48
Burial 1	50
Burial 2	54
IX. Conclusion	57
X. Resources	60
XI. Appendix I	
1a. Inventory Recording Form	
1b. Dental Inventory: Visual Recording Form	
1c. Dental Measurement	
1d. Anthropometrics	
1e. Non-Metric Traits	
1f. Photographic Inventory	
1g. Photographic Log	
XII. Appendix II	
2a. Inventory Recording Form	
2b. Dental Inventory: Visual Recording Form	
2c. Dental Measurement	
2d. Enamel Defect Measurement	
2e. Anthropometrics	
2f. Non-Metric Traits	
2g. Photographic Inventory	
2h. Photographic Log	

Section I Introduction

On July 7, 2004, archaeologists from the Bermuda Maritime Museum and the College of William and Mary arrived on Guana Island in the BVI as part of the ongoing investigation of the island's archaeological and architectural heritage sponsored by the island's owners, Dr. Henry and Gloria Jarecki. Upon their arrival, the archaeologists were informed of the discovery of human remains on the island and subsequent recovery efforts by the Road Town Police.

In the days that followed, archaeologists Mark Kostro and Dr. Marley Brown contacted the Institute for Historical Biology (IHB) at the College of William and Mary in order to notify the staff of the human remains' discovery. Police Commissioner Barry Webb granted their request for custody of the remains for assessment and analysis pending a preliminary inventory to be carried out at the Road Town Police Station. Mark Kostro and Melissa Eaton, Anthropology graduate students from the College of William and Mary, carried out the requested preliminary inventory on July 30, 2004 with materials provided by the Institute for Historical Biology. Dr. Marley R. Brown III, research professor at William and Mary, provided additional assistance with the inventory. The inventory was carried out in the presence of a representative of the Royal British Virgin Islands Police Service, Constable Forbes Washington.

Dr. Michael Blakey, Dr. Marley Brown and Dr. Henry Jarecki (Guana Island Hotel Corporation) arranged for a complete inventory, assessment and analysis of the remains to be conducted by the IHB on the College of William and Mary campus. The remains were shipped via FedEx and arrived at the IHB on 24 November, 2004. The laboratory portion of the project began on 17 May 2005 and was completed on 1 August 2005. The results of the laboratory work as well as subsequent interpretations are included in this report. Dr. Michael Blakey supervised the project in its entirety; Autumn Barrett, Mark Kostro, Fred Lumb and Shannon Mahoney conducted the inventory, assessment and analysis of the remains. The project report was completed by Michael Blakey, Autumn Barrett, Mark Kostro and Shannon Mahoney.

The Institute for Historical Biology would like to thank Dr. Henry Jarecki for the opportunity to examine these remains. We would also like to acknowledge Dr. Marley Brown, Dr. Edward Harris and Mark Kostro for their role in the proper care of these burials.

Section II Historical Background

The British Virgin Islands

The human occupation of the Virgin Islands began some 2000 years before present, long before the arrival of Europeans into the Western Hemisphere. The first people to inhabit the small cluster of islands today known collectively as the 'Virgin Islands group' arrived via a series of migrations from the Orinico River Basin in Venezuela. Archaeological evidence from both the U.S. and British Virgin Islands suggest a succession of occupations of the islands by Amerindians, the latest terminating within a century of the arrival of Christopher Columbus in 1493 (Bates 2001, Righter 2003).

Columbus' ships passed by the islands on his second voyage to the West Indies, naming the group of them "Las Virgines," in reference to the legend of St. Ursula and her 11,000 martyred virgins. In the ensuing years, the Spanish made little effort to settle the islands, establishing only a copper mine on Virgin Gorda in the early seventeenth century. The islands emerged as a favorite hideaway for pirates waiting to attack Spanish galleons carrying looted treasure back to Spain in the sixteenth and seventeenth centuries according to local tradition (Lewisohn 1966:5-9).

As Spain declined as a colonial power in the seventeenth century, Dutch interests in the Caribbean expanded significantly with the founding of the Dutch West India Company in 1621. In 1648 Dutch merchants established the first permanent European settlement in the Virgin Islands on the island of Tortola. By 1672 the English had gained control of Tortola from the Dutch, and in 1680 had also gained control of the nearby islands of Anegada and Virgin Gorda. In 1672 the Danes also moved into the Virgin Islands and established a settlement on the previously uncolonized island of St. Thomas (Lewisohn 1966:9-12).

In the 1690s, the British Virgins took on their first form of organized colonial government. Over the next twenty-five years, a steady influx of planters from England, North America and other islands in the West Indies came into the British Virgins gradually transforming its economic base from smuggling to agriculture, resulting in a plantation economy largely dependent upon enslaved labor to produce cotton, sugar cane, ginger and indigo. Historian Issac Dookhan suggests that a large number of these planters may have come from within the Caribbean. In his documentary history of the British Virgin Islands Dookhan notes, "the population included those who 'had fled from Barbados and the greater islands (of the Leeward Islands) for debt, or to avoid the punishment of their crimes, and have since been increased by pirates, who have come in upon acts of Grace, and are married and settled there'(1975:24). Additional archival research aimed at more specifically pin-pointing where these planters immigrated from before settling in the British Virgins is currently underway.

As more and more planters moved in, they brought with them enslaved Africans and Afro-Caribbeans to work in the fields, factories, and as domestic servants. Additional enslaved persons were purchased from the Danes in St. Thomas where they were less expensive to purchase than in the British colonies. When sugar production became the main export of the islands in the eighteenth century, the demand for laborers led planters to import captives directly from Africa. The first census of the islands was taken in 1717, and indicates there were 159 whites and 175 blacks on Tortola, and 317 whites and 308 blacks on Virgin Gorda. Three years later, the census indicates 1122 whites and 1509 blacks for the whole of the British Virgins (Dookhan 1975:71; Lewisohn 1966:12-13).

According to a report to the Board of Trade & Plantations, the agricultural output of the islands in 1740 included “sugar, molasses, rum, cotton, lime juice, ginger, indigo, coffee, aloe, pimentos, turtle shell, mahogany, timber and plank was to the value of 30,000 pounds sterling (Lewisohn 1966:16).” By 1743 over one million pounds of cotton were being exported from the colony, along with a thousand hogsheads of brown *muscadado* sugar that was being sent to England. Molasses and rum, co-products of the sugar manufacturing process, were produced for local consumption and for shipment to the North American colonies (Lewisohn 1966:15).

In the last quarter of the eighteenth century, the plantation economy of the Virgin Islands declined as it did throughout much of the Caribbean. Waning profits, hurricane damage, and increasing organized resistance to slavery by the enslaved people themselves, all contributed to collapse of the region’s economy. By the turn of the century, planters in the Virgin Islands were abandoning their plantations and retreating to England or North America. The slave trade in the British West Indies was ultimately halted in 1807, and emancipation took place in 1834. At the time of emancipation, there were over 9,000 persons of African decent living in the British Virgin Islands (Lewisohn 1966).

Guana Island

The first planters are believed to have settled on Guana Island in the 1720s or 30s.¹ European derived artifacts collected from various locations across the island consistently indicate the island’s plantation-period occupation began in the second quarter of the 18th century. These settlers quickly went about altering the island’s landscape for sugar cultivation and processing. On Guana, as throughout the Caribbean, enslaved Africans and Afro-Caribbeans cleared the fields and built the factories in which these same individuals would later toil, often suffering significant personal injuries as a result. Numerous contemporary accounts detail the difficult and dangerous work carried out on sugar estates. In addition to the cumulative degenerative effects of heavy labor in the tropics, it was not uncommon for field hands to suffer deep cuts from errant machete swipes; for mill workers to have their

¹ Recent archaeological finds indicate that prior to European colonization, Guana had been occupied by Amerindians sometime between 600-1200 AD.

hands crushed in milling machinery; or for boiling house workers to receive burns from stoking the boiling house furnaces and from working around the scalding-hot sugarcane juice, among other injuries.

The evaluation of the physical evidence relating to Guana's plantation operations has been the focus of recent archaeological investigations. The above-ground remains of Guana's eighteenth-century factory complex, including the animal-powered crushing mill, sugar boiling house, curing house, and rum distillery have all survived to the present day. Also surviving are the foundations of a plantation great house overlooking the island's small agricultural plain. The ruins of a second great house had also survived into the early twentieth century, but are currently inaccessible under the modern-day resort facilities (Barka et al. 1999). Recently, the ruins of building and houseyard for the quartering of enslaved Africans and Afro-Caribbeans during the eighteenth-century plantation period has also been identified (Kostro et al. 2005).

As is the case for eighteenth century sites throughout the Caribbean, the documentary evidence of Guana's plantation-period occupation is minimal. Local tradition suggests that Guana was divided between two Quaker families in the eighteenth century, the Parkes and the Lakes. Quaker missionaries founded a settlement at Fat Hog Bay on Tortola in 1727, roughly coinciding with the archaeological evidence for the establishment of Guana's plantation operations. Indeed, both the Parke and Lake family names are attributed to Guana in the surviving records of the Tortola Society of Friends, as well as, in the correspondence of Quakers from both North America and England (Jenkins 1923). From the Quaker records we know that the Parke household consisted partly of James Parke and his wife, Bytha (possibly Tabitha). They had two children while living on Guana. John, born in 1741, died less than a year later. Their second child was a daughter, Dorcas. By 1754 James Parke was known as the "widower of Guanah Island", and was remarried to Mary Vanterpool (Jenkins 1923:75). The *Minutes of the Men's Monthly Meeting* also indicate that James Parke was appointed Treasurer of the Tortola Meeting in 1743, but resigned in 1749 (Jenkins 1923:31,78). Several different Lakes are mentioned in the records, but it has not yet been determined if they are all related, and if so, if they all lived on Guana. Among them are: Jonas and Elizabeth Lake and their two daughters, Ann and Miriam; Sarah Lake who married Thomas Humphreys; John Lake; James Lake; and William Lake (Jenkins 1923:31,75,77-78). The local Quaker community, however, was fairly short-lived, lasting for no more than 45 years. The Monthly Meeting of the Society of Friends on Tortola was officially ended in 1762. Very little else is known about either the Lake or Parke families, including how long they remained on Guana.

While the documentary record of Guana's planter families is sparse at best, records relating to the enslaved people living and working on the island are virtually non-existent. Among the few possible mentions of enslaved persons on Guana includes a reference in the *Minutes of the Men's Monthly Meeting* where James Lake, one of the planters on Guana, complained that his mother-in-law had kept from him "two negroes" (Jenkins 1923:31). For the late eighteenth century, nothing is known

about Guana's enslaved people. The next reference to any persons on Guana is not until 1811 when seventeen enslaved persons were emancipated and allotted 300-acres on the island. It is not clear, however, if these people were residents of Guana Island at the time of their emancipation (McGlynn 1980:55).

The preliminary archaeological evidence suggests that the island was not inhabited past the first quarter of the nineteenth century (Kostro *et al.* 2005). The only other reference to Guana before the twentieth century is a mention to the use of the island for cattle grazing in the 1860s by members of the Long Look community on Tortola (McGlynn 1980:91, 180).

In 1935 Guana Island was purchased by the Bigelow family of Massachusetts from the Frett and Shirley families of Road Town with the idea of running the island as a commune. It subsequently took on the nature of a hotel. In 1975 the island was sold to the Jarecki family of New York, who has run a small hotel and resort on the island. Since the Jarecki's purchase, the island has also served as a nature reserve and wildlife sanctuary, boasting more flora and fauna than any island of its size in the Caribbean.

Section III

Environmental and Archaeological Background

Surrounding Environment

Located across a narrow channel from the east end of the island of Tortola, Guana Island measures no more than 850-acres in total area. The geography of the island consists of two small peaks separated by a narrow level plain known locally as the “flats.” The flats are bounded by the steep slopes of the island’s two peaks to the northwest and southeast, by a salt pond to the northeast, and shallow bay to the southwest facing toward the island of Tortola. During the island’s plantation period in the eighteenth century, the flats and the slopes of the surrounding hillsides were reportedly planted with sugar cane.

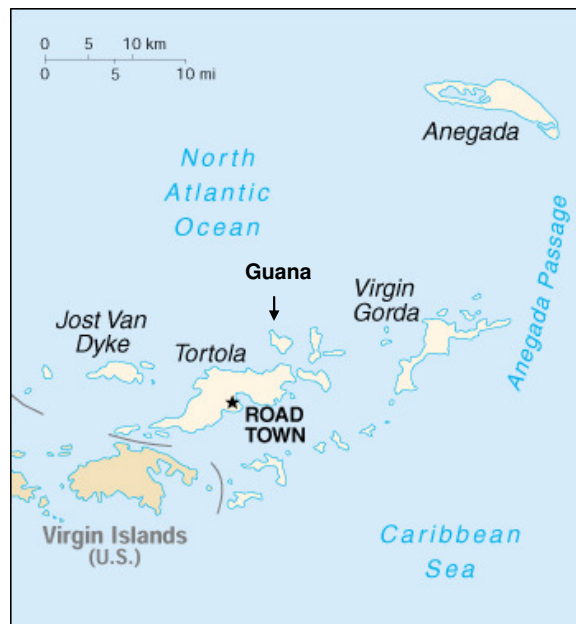

Figure 3.1: Map of the Virgin Islands.

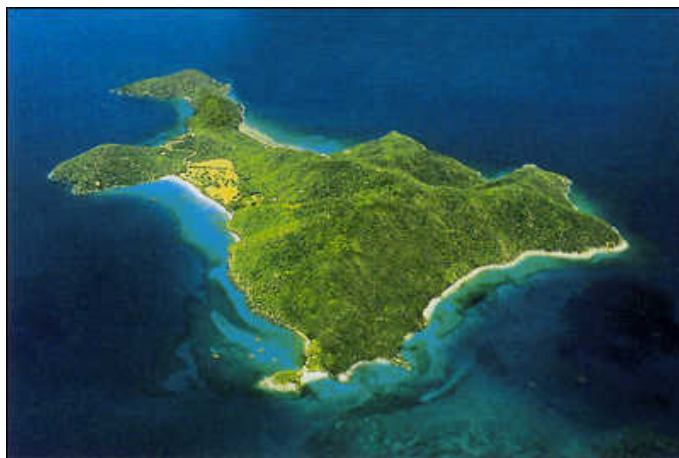

Figure 3.2: Aerial photo of Guana Island.

The burying ground on Guana Island is located to the southeast of the present-day Beach House at White Bay Beach. The burying ground is located on the landward side (southeast) a line of low sand dunes that parallel the coastline of the bay. The dunes are covered with scrub vegetation that prevents their erosion. At the time of these investigations in July 2004, a beach-side massage stand was under construction among the sand dunes immediately adjacent to the burying ground's location. A dirt road oriented parallel to the coastline crosses over the burying ground at its northeastern extent. During the archaeological investigations of the site, at least one burial was noted to extend under the roadbed. The areas to the northwest and southeast are covered in grass.



Figure 3.3: Site before excavation.

The average high-water line along the beach is more or less 40-meters to the southwest of the burying ground, and it is located at an elevation within two-meters of sea level. The soil in this area consists primarily of white beach sand covered with a thin organic layer. According to the hotel staff, this area of the flats is particularly vulnerable to flooding during hurricanes and other heavy storms.

Other notable landscape features include the recently identified ruins of a quarter for housing enslaved Africans and Afro-Caribbeans. The quarter and the burying ground are hypothesized to be contemporary with one another. The building is located approximately 70-meters to the southeast of the burying ground, and is similarly positioned between the sand dunes and the dirt road that parallel the beach at White Bay.

Archaeological Site Context

In late June 2004, routine excavations for new electricity and water lines to the southeast of the present-day Beach House at White Beach inadvertently encountered the human skeletal remains. Upon their discovery, the Royal British Virgin Islands Police Service was called in to investigate the scene. Officers from the police carried out forensic excavations aimed at recovering additional remains and other evidence that would be useful in determining whether or not the remains were related to criminal activity. As a result of their efforts, the fragmentary skeletal remains of two individuals were recovered and taken for analysis to the Road Town Police Station on Tortola. A preliminary examination of the skeletal remains at the Police Station determined that the remains were most likely not related to any recent criminal activity, and were hypothesized to be the archaeological remains of past inhabitants of Guana Island.

In July 2004, a brief archaeological investigation of the burial site was carried out in the hopes of finding additional evidence that would be useful towards determining the relative antiquity and cultural affiliation of the two exhumed burials (Kostro 2004). Initially the investigation consisted of re-examining the burial site already examined by the police. These efforts involved passing of the sand excavated by the police through standard $\frac{1}{4}$ -inch hardware mesh archaeological screens in an attempt to recover any small bones or other objects, such as grave goods or coffin hardware that may have been missed during the police department's recovery efforts. Screening of the excavated soils resulted in the recovery of numerous small fragments of bone and a small number of artifacts. Most of the bone fragments recovered were very fragile facial bones that make up the anterior portion of the skull. In addition, individual teeth were recovered; several small finger and toe bones were found, as well as a single patella (kneecap). Non-skeletal material recovered included numerous heavily corroded iron nails and nail fragments, many of which had small fragments of wood still attached to them. The recovery of the nails in association with the burials indicates that the individuals were probably buried in wooden coffins. The fact that these individuals were likely interred in coffins is a further indicator that the burials are of historic rather than prehistoric age. The type of nails is another important clue to the age of the burials. All the nails recovered were hand wrought nails made by a blacksmith, and were most commonly in use during the seventeenth and eighteenth centuries. In addition, three bone buttons, a lead musket ball, and a cowrie shell (*Cypraea cinerea*), an indigenous species of cowrie sometimes used for adornment or for ritual purposes by the enslaved Africans in the Caribbean, were recovered. The nails, buttons, and musket ball are all artifacts typically recovered on archaeological sites dating to the eighteenth century.



Figure 3.4: Burial Ground excavation.

The recovery of the musket ball in association within the burial ground suggests the possibility that the cause of death for one of the individuals buried on Guana was from a gun shot wound. The musket ball is asymmetrical, measuring 50 to 54mm in diameter, a caliber that is consistent with ammunition used in eighteenth-century pistols (William Pittman, personal communication). However, because it was recovered from a disturbed context, and not in direct association with a specific burial, prohibits the attribution of a gun shot to a specific individual as a cause of death.

Subsequent to the initial site investigation, additional controlled excavations of the burial site were carried out to delineate the limits of the burying ground and to estimate the number of individuals interred. A front-end loader was used to remove the upper 50cm of sand from an area measuring 5x6 meters adjacent to the location of the disturbed burials. Additional excavation was done by hand using trowels and shovels. No burial shafts were evident in the bleached white sand. Instead, additional burial locations were determined from concentrations of coffin nails and organic stains left in the sand by the decomposition of the wooden coffins in which the deceased had been interred. Within this area, nine additional burials were located, indicating a minimum number of eleven interments within the burying ground. Their locations and orientations were recorded, but the burials were left undisturbed *in situ*. The small size of some of the interments indicates the burying ground includes children as well as adults. Unfortunately, the limits of the site could not reliably be determined from the excavations, and additional burials are likely to exist in all directions around the excavated block. At this time, no additional remains have been removed from this site.

Section IV

Preliminary Inventory and Condition of Remains

Following the determination that the burial site on Guana Island was an archaeological site rather than the site of a recent burial, the custody of the skeletal remains and associated materials recovered by the Royal British Virgin Islands Police Service was transferred to representatives of the Guana Island Archaeological Project. This was done in order to conduct more extensive bioarchaeological laboratory analysis of the remains that would allow for a more conclusive determination of the age of the individuals at death, their sex, population affiliations, and to investigate biological indicators relating to their quality of life.



Figure 4.1: Melissa Eaton and Marley Brown unpacking the human remains at the Police Station.

The skeletal remains were received in two Hollinger-style boxes along with a single large brown paper bag that contained some of the larger elements. The remains of the two individuals were commingled and loosely packed. The remains were unpacked at the police station in Roadtown, then separated by individual and laid out in correct anatomical position. A general inventory of elements was recorded and the condition of the remains noted.

One individual (Burial 1) was represented by a nearly complete skeleton; the second individual (Burial 2) however, consisted only of a cranium and mandible, but no post-cranial elements. Evidently, at the time of excavation, the post-cranial elements of Burial 2 were left *in situ* at the site. Most likely, the post-cranial portion of Burial 2 lies buried in the unexplored area to the southwest of the excavations.

In general, all the bones received were well preserved, and in stable condition with no evidence of post-mortem exposure to weather, rodents or other natural

disturbances. Damage to the bones inflicted at the time of their discovery and excavation, however, included severe damage to the anterior (face) portion of Burial 2's skull which was nearly completely crushed. Other damage inflicted during discovery and recovery included: a broken scapula, broken Os Coxae (pelvis), two broken humeri, two broken radii, two broken ulnae, 22 vertebrae in various degrees of fragmentation, and 41 rib fragments. All the remaining elements were complete with varying degrees of surface abrasion and nicks received from shovels and mechanical excavator during excavation.

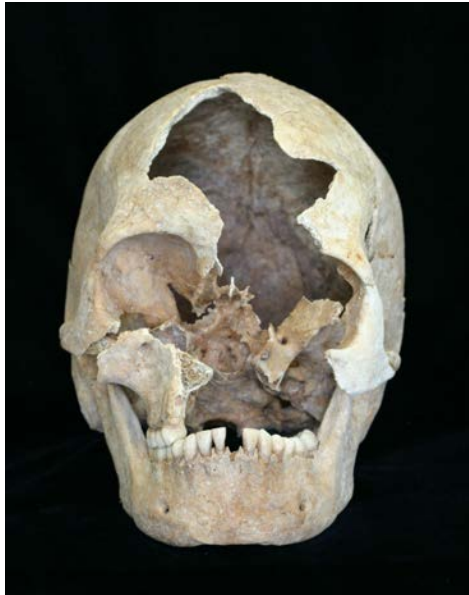

Figure 4.2: Burial 2 – Anterior view of skull showing excavation damage.

After accepting custody of the remains in Road Town, they were cleaned using a dry tooth brush to remove any loosely adhering sand matrix. After cleaning, the remains were repacked for transportation to the Institute for Historical Biology at the College of William and Mary in Williamsburg, Virginia USA. Transportation of the remains to Williamsburg was generously provided for by Dr. Henry Jarecki.

Section V

Laboratory Methodology

Two teams, of two people each, assembled at the IHB for the Guana Project. Before the laboratory inventory, assessment and analysis began, the remains were cleaned a second time with a dry, soft-bristled brush and deionized water was used to clean dentition in order to facilitate observation. Any grains of sand or small fragments of bone that were dislodged during the examination were collected and stored in a plastic bag in order to retain association with the burials.

The inventory verified the in-field assessment of two individuals; a nearly complete skeleton of an adult male (Burial 1) and a fairly gracile cranium and mandible of an adult female (Burial 2). Overall, there is a remarkably high degree of preservation and completeness for Burial 1 although most of the distal phalanges for the hands and feet, the third metacarpal on the left hand and a few of the teeth are noticeably absent (Appendices 1a and 2a).

Bone fragments that were recovered from excavated soil were identified, sorted and placed with the proper individual. In order to assess the completeness and state of preservation for each burial, the inventory was conducted using the "Inventory Recording Form for Complete Skeletons" from the Standards for Data Collection from Human Skeletal Remains (Buikstra and Ubelaker 1994). The dental inventory, dental morphology, dental measurements and recordation of enamel defects were also conducted using forms from the Standards or a modified version of the Standards format (Appendices 1b – 1c and 2b – 2d).

Measurements of each element were taken for comparative purposes, to determine stature and can be used to assess for sex. In order to facilitate anthropometric measurements and achieve accurate results, a few of the elements were mended with B-72, an acrylic adhesive. Measurements were taken using a combination of spreading calipers, dental calipers, an osteometric board and mandibulometer. The two teams measured each element from the two sets of remains. After each team took independent measurements, the results were compared and averaged (Appendices 1d and 2e). Non-metric traits were also recorded and can be a valuable tool for examining genetic familial traits (Appendices 1e and 2f).

Age, sex, pathologies and occupational markers were assessed for each individual. During the assessment phase, each element is observed for distinguishing morphological characteristics and irregularities in bone formation indicative of aging, disease, injury and physiological stress. Age was primarily determined through observations of cranial sutures, stages of epiphyseal fusion, and dental wear. Sex was determined through observations of morphological features on the crania of both individuals as well as the innominates of Burial 1.

Observations of pathology and occupational indicators were recorded by element using a modified version of the Standards pathology codes. The modified coding

system was developed for the New York African Burial Ground project and provides a thorough and efficient way of recording multiple pathologies.

Each element was photographed for inventory and reporting purposes (Appendices 1f, 1g, 2g and 2h). The remains are currently being kept at the Institute for Historical Biology in a locked and humidity-controlled cabinet.

Section VI
Demographic Information (Age, Sex and Population Affiliation)

Burial 1

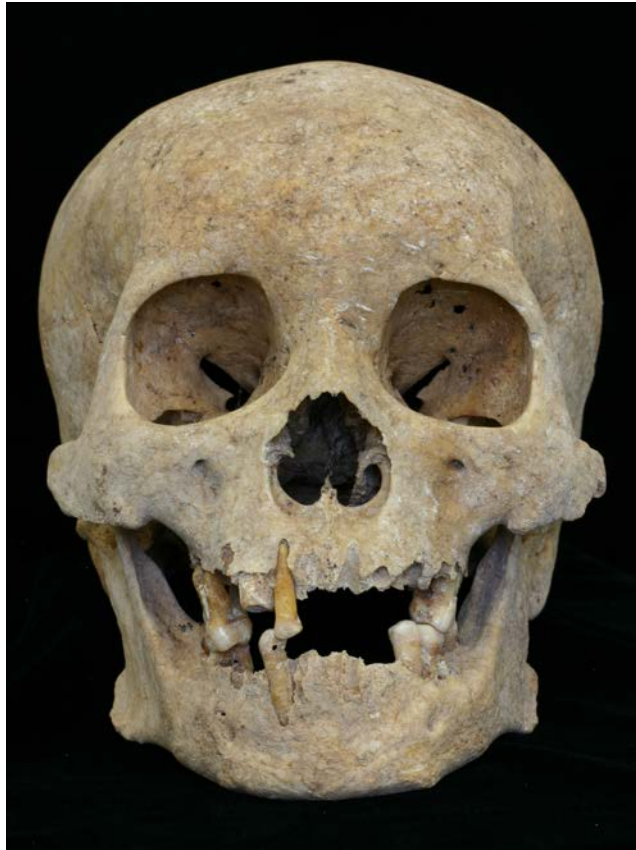


Figure 6.1: Burial 1 - Anterior view of skull.

Age

Age ranges are determined using observations of dental attrition, epiphyseal fusion as well as morphological changes in the cranium, ribs and innominates. Each feature is given a score based upon characteristics of fusion, wear or changes on the surface of the bone (Buikstra and Ubelaker 1994). Although observations of particular features prove to be more reliable than others (e.g. pubic symphysis), the evaluation of several features both independently and collectively provided the strongest assessment of age.

Cranium



Figure 6.2: Burial 1 - Superior view of cranium, showing obliteration of cranial sutures (anterior at the top of the image).

General observation of cranial suture closure indicated that this individual was likely an older adult (Figure 6.2). Using the scoring system in the Standards (Buikstra and Ubelaker 1994), all of the cranial sutures for Burial 1 reaffirmed that the sutures were either completely obliterated or show signs of significant closure (Tables 6.1 and 6.2).

Table 6.1

Cranial Vault Suture Site	Score*
Midlambdoid	2
Lambda	3
Obelion	3
Anterior Sagittal	3
Bregma	2
Vault Sutures Composite Score	13
"S" Score	S4
Age Range	30 - 60+ years.
Age Mean	45 years

*Scores range from 0 (open suture) to 3 (complete obliteration).

Table 6.2

Lateral- Anterior Suture Sites	Score*
Pterion	2
Midcoronal	2 or 3
Sphenofrontal	2
Inferior Sphenotemporal	3
Superior Sphenotemporal	2
Composite Score	11 - 12
S Score	S7
Age Range	48 - 60 + years
Age Mean	55 years

*Score is based on 0 (open suture) to 3 (complete obliteration).

While both sets of age ranges seem reasonable, the lateral-anterior suture scores (Table 6.2) seem to reflect the age of Burial 1 more accurately for several reasons. Scoring of the lateral-anterior sutures sites result in more refined age ranges and given the high percentage of complete obliteration on the cranial sutures, it is probable that this individual is older than 48 years of age.

Dentition

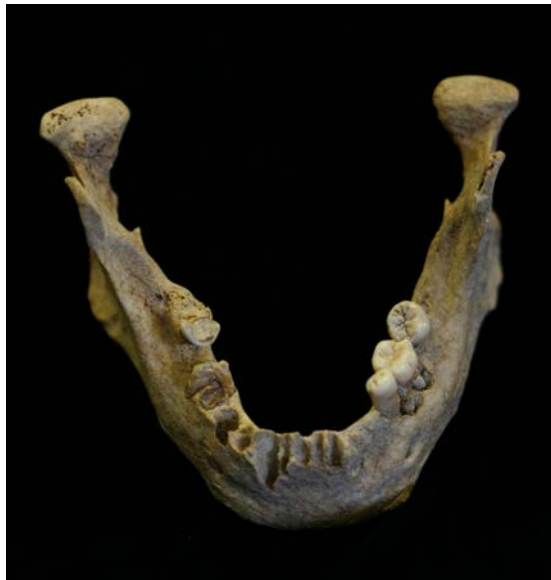

Figure 6.3: Burial 1 - Superior view of mandible.

The significant amount of tooth loss is problematic in determining an age based on attrition for Burial 1 (Figure 6.3). Usually, mandibular molars are examined for wear patterns on the occlusal surface; however, none of the second molars were present. The mandibular left first and third molars and the right third molar are present for observation, however, the molars on the left side exhibit very little sign of attrition

except for some superficial wear facets. The maxillary first molars on both sides also have very little indication of wear which may be attributable to the extent of tooth loss and a lack of occlusion. Nevertheless, based on the wear of the right mandibular third molar as well as the extent of tooth loss and alveolar resorption this person is likely 45 + years old (Brothwell 1963).

Innominate

Articular surfaces on the innominate (pubic symphysis and auricular surface) change in texture and density as an individual ages and can also be used in the determination of potential age ranges.



Figure 6.4: (Left) Burial 1 - Auricular surface on the left innominate.
Figure 6.5: (Right) Burial 1 - Auricular surface on the right innominate.

The left and right auricular surfaces were slightly dissimilar. The right auricular surface exhibited more of the bone density associated with an older age range than the left. The left side still had a granular surface and some faint billowing (Figure 6.4). Both sides have significant microporosity with some macroporosity, loss of transverse organization and some loss of billowing. The superior demiface and apex both have significant lipping with the right apex appearing to be slightly more arthritic than the left. The left and the right are similar in description to Phase 7 (Lovejoy et al 1985) even though some slight asymmetry was noted in their appearance. Phase 7 characteristics have been attributed to individuals between 50 and 59 years of age (Table 6.3).



Figure 6.6: Burial 1 - Pubic symphysis of the left innominate (medial view).

The pubic symphysis has a fine grained surface with a very small amount of lipping on the dorsal and ventral surface (Figure 6.6) similar to Phase 5 of the Suchey Brooks Scoring System attributed to individuals over 25 years of age (Brooks and Suchey 1990). According to the Todd Scoring System, the pubic symphysis started to exhibit signs of erosion on the ventral margin as described in Phase 10 for individuals over 50 years of age (McKern and Stewart 1957) (Table 6.3).

Table 6.3

Innominate and Rib Aging Feature	Phase	Age Range
Auricular Surface	Phase 7	50 – 59 years
Pubic Symphysis – Suchey-Brooks Male	Phase 5	25 – 60 + (mean 45) years
Pubic Symphysis – Todd	Phase 10	50 + years
Rib – Sternal End Ossification (estimate)	Phase 7	56.3 – 66.1 years
Summary Age		50 – 66.1 years old

Ribs

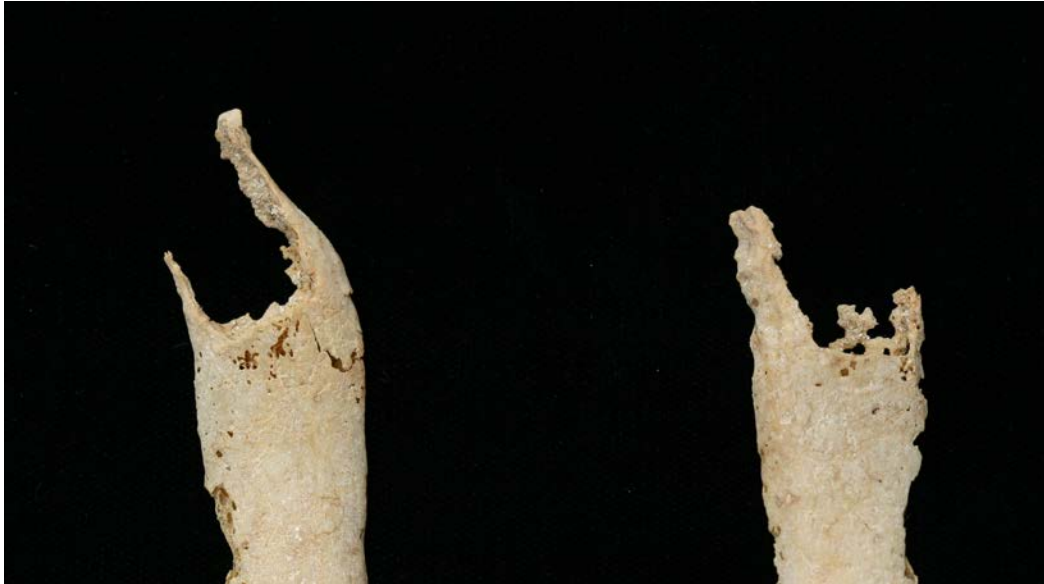

Figure 6.7 – Burial 1 - Sternal end of ribs from the left side showing degree of ossification.

Examination of sternal end ossification in ribs as another method of age determination is especially helpful for older individuals. Cartilage connecting the sternal ends of the ribs with the sternum begins to ossify in older individuals and age ranges are established by the extent of ossification (Figure 6.7). Although the 4th rib is usually the standard rib examined for aging, this sternal end was not present on the right or the left. A sample of sternal ends for the left side were examined and determined to have the qualities similar to those described for individuals between 56.3 and 66.1 years of age (Iskan et al 1984)(Table 6.3).

Age Summary

Examining all of the age determinations cumulatively, the lower end of the age range would be determined conservatively by the lateral-anterior suture sites scoring, at 48 years of age (Table 6.2). The higher end of the age range is best determined by the sternal end of the ribs (Table 6.3) where ossification of cartilage places this individual as old as 66.1 years of age. Therefore, the age for this individual is most likely between 48 and 66.1 years of age.

Sex

Morphological characteristics of the mandible, cranium and innominates can vary by sex in adult individuals. Five features on the skull are scored based on their relative robusticity (male characteristics) or gracility (female characteristics). Five additional features on the innominate are assessed based on the general size and shape of features.

Cranium

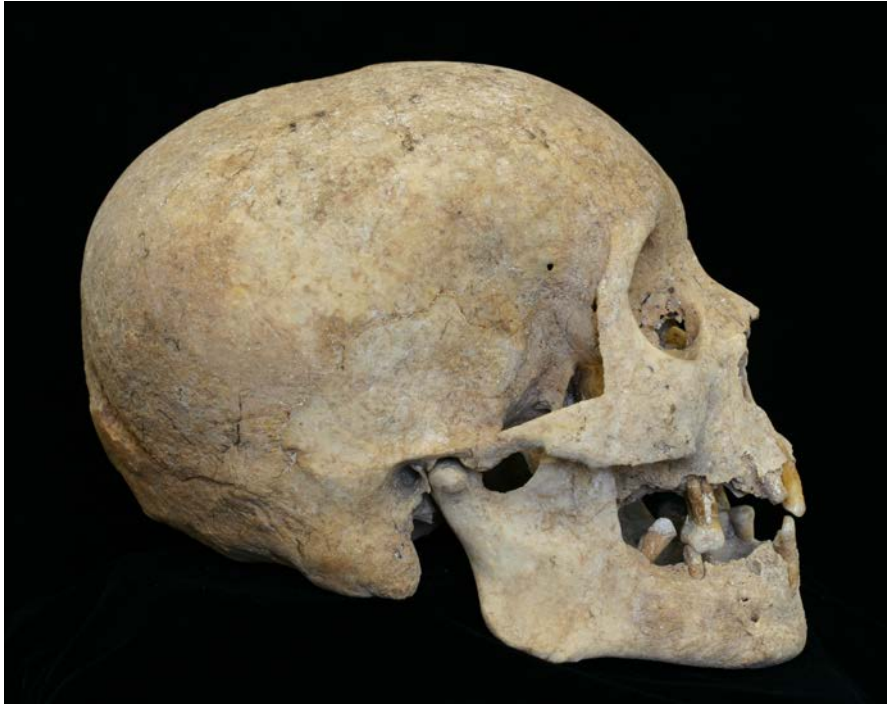

Figure 6.8: Burial 1 - Lateral view of skull.

Although two of the features received “ambiguous” scores independently, general characteristics of the Burial 1 skull are strongly indicative of a male (Table 6.4) (Figure 6.8).

Table 6.4

Cranial Morphology Feature	Score*
Nuchal Crest	3
Mastoid Process	5
Supraorbital Margin	4
Supraorbital Ridge / Glabella	3
Mental Eminence	4
Sex Determination, Skull	5 (Male)

*Score for sex ranges from 1 (female) to 5 (male).

Innominate

All of the morphological features used to determine sex on the innominate were strongly male (Table 6.5).

Table 6.5

Innominate Feature	Scale	Score*
Ventral Arc	1 – 3	3
Subpubic Concavity	1 – 3	3
Ischiopubic Ramus Ridge	1 – 3	3
Greater Sciatic Notch	1 – 5	4
Preauricular Sulcus	1 – 4	4
Estimated Sex, Pelvis	1 – 5	5 (Male)

*Note that scoring varies between 1 (female) to either 3, 4 or 5 (male) depending on which method is used.

Stature

Using length measurements taken from long bones of the arm and leg, stature was assessed using the Trotter and Gleser (1952) estimates published in Bass (1995). The individual from Burial 1 was estimated to be between 5 feet 8 inches and 5 feet 11 inches tall (Table 6.6).

Table 6.6

Element	Length (mm)	Stature Estimate (cm)
Humerus	351	176
Radius	284	179
Ulna	309	181
Femur	479	172
Tibia	411	175
Fibula	410	176

Population Affiliation

Population affiliation for this individual is an approximation based on morphological characteristics provided in Bass (1995: 86-93), primarily derived from facial features of the skull. Craniometric measurements, though recorded for this individual, are not reliable in assessing population affiliation without a statistically significant sample size.

Occlusion was not observable due to tooth loss. This person has a slightly prognathic profile and a rounded forehead. The shape of the maxillary bones from the alveolar portion to the nasal aperture exhibits “nasal guttering.” A slight depression is present at the bregma craniometric point. There is no depression at the nasal root and the base of the skull are broad or “flared.” These features, are more frequently exhibited in West and Central African populations than in other populations with historic ties to Guana. This individual has slightly projecting zygomatics, a trait most frequent within Native American populations, but observed in varying degrees across all populations.

The general cranial morphology is consistent with the archaeological and historical context, indicating West or Central African ancestry with Native American ancestry of secondary possibility and European ancestry least likely.

Burial 1 Summary

Burial 1 is a 48 – 66.1 year old man standing between 5’ 8” and 5’ 11”, likely of African descent.

Burial 2

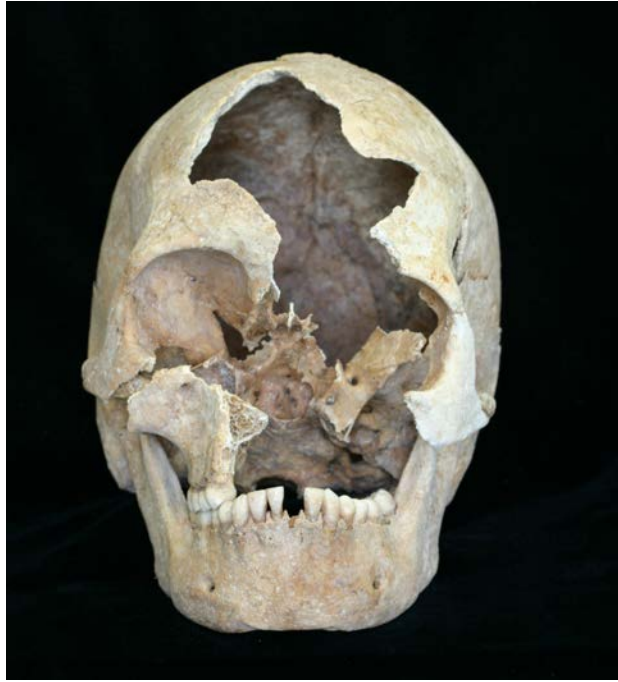

Figure 6.9: Burial 2 – Anterior view of skull.

Age

Cranium

Observations for Burial 2 were complicated by a marked asymmetry in the cranial sutures (discussed further in Section VII), damage to the left side of the cranium, and taphonomic responses to wet / dry conditions. The Standards scoring for lateral-anterior sites are exclusive to the left side of the cranium, however, the sutures appear to be more open on the left and appear more closed and “complicated” on the right side. In addition, the left portion of the frontal was not available for observation and, as a result, scoring for portions of the lateral anterior sites was listed as “unobservable.” In order to accommodate these differences, both the left and right lateral-anterior sutures were scored (Tables 6.8 and 6.9).



Figure 6.10: Burial 2 - Superior view of cranium (anterior to the left of the image).

Table 6.7

Cranial Vault Suture Sites	Score*
Midlambdoid	1
Lambda	1
Obelion	1
Anterior Sagittal	1
Bregma	0
Vault Sutures Composite Score	4
"S" Score	S2
Age Range	22 - 45 years
Mean	34 years

*Scores range from 0 (open suture) to 3 (complete obliteration).

Table 6.8

Left Lateral- Anterior Sutures Sites	Score*
Pterion	0
Midcoronal	unobservable
Sphenofrontal	unobservable
Inferior Sphenotemporal	1
Superior Sphenotemporal	unobservable
Composite Score (estimate)	1
"S" Score	S1
Age Range	19 - 42 years
Age Mean	31 years

*Scores range from 0 (open suture) to 3 (complete obliteration).

Table 6.9

Right Lateral- Anterior Sutures Sites	Score*
Pterion	1
Midcoronal	1
Sphenofrontal	1
Inferior Sphenotemporal	1
Superior Sphenotemporal	1
Composite Score	5
“S” Score	S3
Age Range	27 – 51 years
Age Mean	40 years

*Scores range from 0 (open suture) to 3 (complete obliteration).

Taking the conditions of the remains into consideration, the age ranges for the left and right lateral-anterior suture sites most likely do not reflect the proper age ranges. Nevertheless, the age ranges derived from the lateral-anterior sites overlap with the age range determined by the cranial vault suture sites (Table 6.7). Relying on the examination of cranial vault sutures, this individual is in the 22 – 45 year-old age range.

Dentition

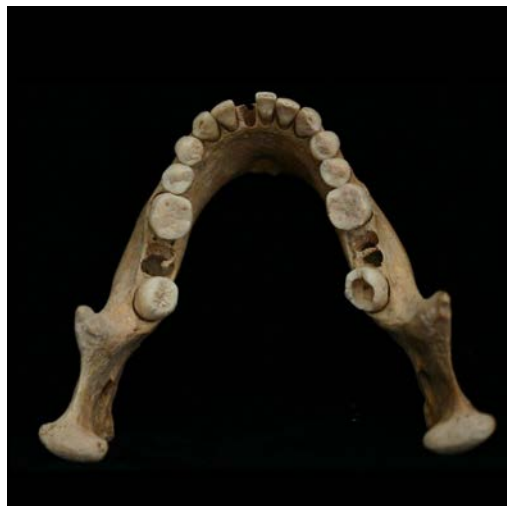

Figure 6.11: Burial 2 - Superior view of mandible.

All of this individual's permanent teeth, including the third molars, have erupted and the molars have started to show signs of wear. Solely based on the degree of attrition on the first and third mandibular molars, this person falls into the 17 – 25 year age range (Brothwell 1963). Some dentin exposure is present in the cusp areas of the first molars suggesting that the individual was in the middle to latter portion of this range.

Age Summary

Establishing the lower limit of the age range by examining the cranial sutures and the higher limit of the age range by dental attrition, this individual is between 22 and 25 years of age.

Sex

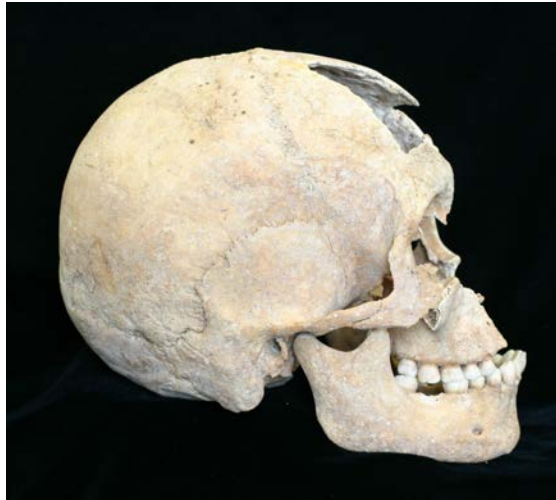

Figure 6.12: Burial 2 - Lateral view of skull.

Overall, the cranium associated with Burial 2 is gracile and cranial morphology indicates that this individual is definitely a female (Figure 6.12) (Table 6.10).

Table 6.10

Cranial Morphology – Feature	Score*
Nuchal Crest	1
Mastoid Process	1
Supraorbital Margin	2
Supraorbital Ridge / Glabella	1
Mental Eminence	2
Estimated Sex, Skull	1

*Score for sex ranges from 1 (female) to 5 (male).

Burial 2 Summary

Burial 2 is a 22 – 25 year old woman.

Section VII Pathology

Observations of pathologies are discussed in four separate categories: Developmental / General Stress Indicators, Diet / Nutrition, Infection and Musculo-Skeletal. Although it is helpful to categorize the pathologies separately to facilitate discussion of their causes and manifestation, it is important to remember that several of these pathologies are interrelated. The purpose of the pathology section is to describe the manifestation and immediate cause of each pathology. The activities and illnesses contributing to these skeletal pathologies and their relation to the individual's health are discussed in Section VIII of this report.

Burial 1

Developmental and General Stress Indicators

Dental Crowding / Malocclusion / Development

There is noticeable dental crowding on the anterior portion of the maxilla resulting in the right maxillary premolar being located medially to the right maxillary second premolar. The cause for the dental crowding in this individual cannot be determined and is simply understandable as a familial trait.

The impacted third molars grew in at a 45 degree angle above the jawline, likely pressing against the second molars. Both the maxillary and mandibular second molars are absent and the alveolar bone has completely resorbed. As a result of the combined effect of dental crowding and the third molars erupting, the second molars might have been voluntarily removed to relieve some of the pressure.

It also appears that roots of the mandibular right central and lateral incisor fused just behind the alveolar bone (Figure 7.5). No immediate cause for this condition can be determined.

Sacrum

The length of the sacrum (86.845 mm) is noticeably short for an adult male of this stature. The sacral index (125.68), a relative ratio of length to width, falls outside of the ranges provided for both males and females (Bass 1995) primarily due to the length being disproportionately small when compared to the width. Although no immediate cause can be determined, it is likely that this is related to issues of early development for this individual.

Exostoses on the External Auditory Meatus

Exostoses (spicules of bone) of the external auditory meatus (EAM) and the inferior aspect of the temporals were observed bilaterally and “may be associated with inflammation and infections of the ear, which are often associated with swimming and exposure to cold water (see Hutchinson et al. 1997)” (Blakey and Barrett 2004). The exostoses manifested in the form of spiculation rather than a bony nodule inside the EAM. Exostoses for Burial 1 are considerably less severe than those of Burial 2.

Diet / Nutrition and Disease

Periodontal Disease / Abscess

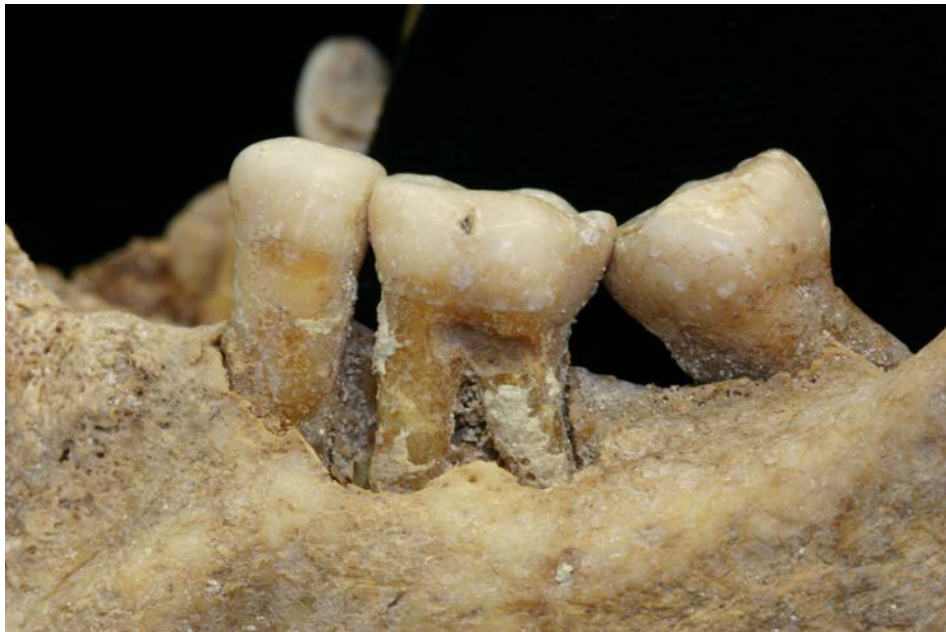

Figure 7.1: Burial 1 – Left lateral view of mandible (anterior to the left in the image), showing abscess, carious lesion on LM₁ and alveolar reduction.

The adult male had reached advanced stages of periodontal disease and tooth loss. The alveolar bone receded, exposing a considerable amount of each tooth's root. The roots of the mandibular 1st molar on the left have been exposed by a combination of an alveolar abscess and recession (Figure 7.1). The mandibular 1st molar on the right has completely rotted away as the result of an advanced carious lesion.

The alveolar portion of the maxilla is also considerably resorbed and, just prior to death, the first molars on both the left and right sides were very loose and were probably primarily held in place by the gums. Just before he died, perhaps within six months, this individual lost his left mandibular canine as the socket is showing the onset of resorption (Figure 7.2).

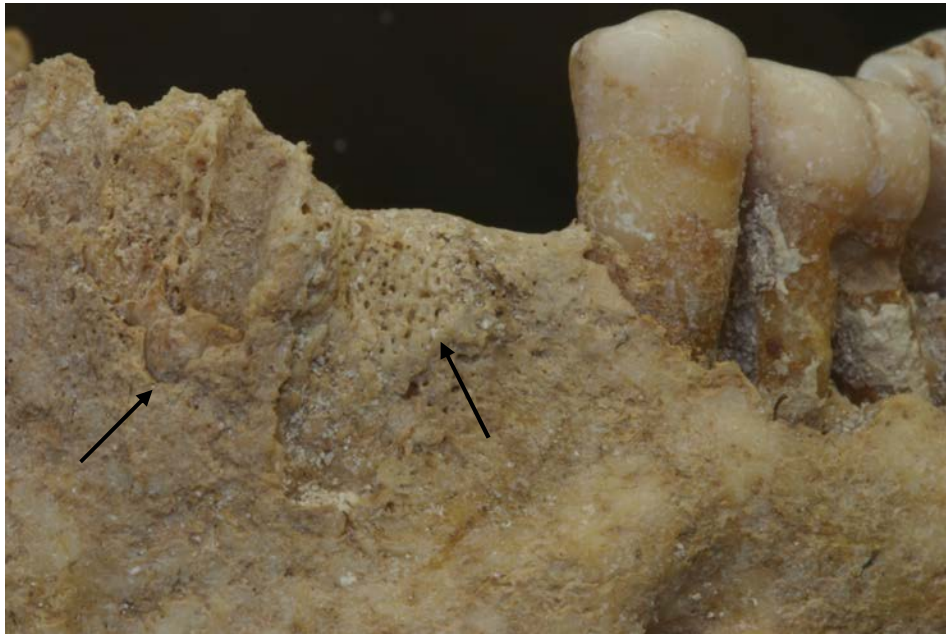

Figure 7.2: Burial 1 – Anterior / Left Lateral portion of the mandible, showing remodeling for the canine tooth socket and fusion of roots in incisor sockets.

There is a considerable amount of plaque (calculus) deposited on both the enamel surface and the roots indicating that the roots have been exposed over an extended period. White explains that the accumulation of plaque is often a precursor to carious lesions (1991:352) and in the case of Burial 1, as the roots gradually became exposed due to alveolar recession they accumulated plaque and subsequent carious lesions.

Tooth loss, for this individual, was a result of a number of factors including carious lesions, alveolar recession from periodontal disease, abscesses and may also include voluntary removal of the second molars.

Pitting/ Porous Bone

Several stages of bone loss with varying conditions and causes were observed for Burial 1. The older male displayed pitting on the maxilla, palate, zygomatic, temporals, occipital and sphenoid as well as each of the eye orbits. These areas of pitting and porous bone on the cranium are being distinguished from incidences of porotic hyperostosis due to the lack of diplotic expansion and the facial distribution pattern of pits. Their immediate cause is associated with inflammation and infection in surrounding tissues (see discussion on scurvy at the end of this section).

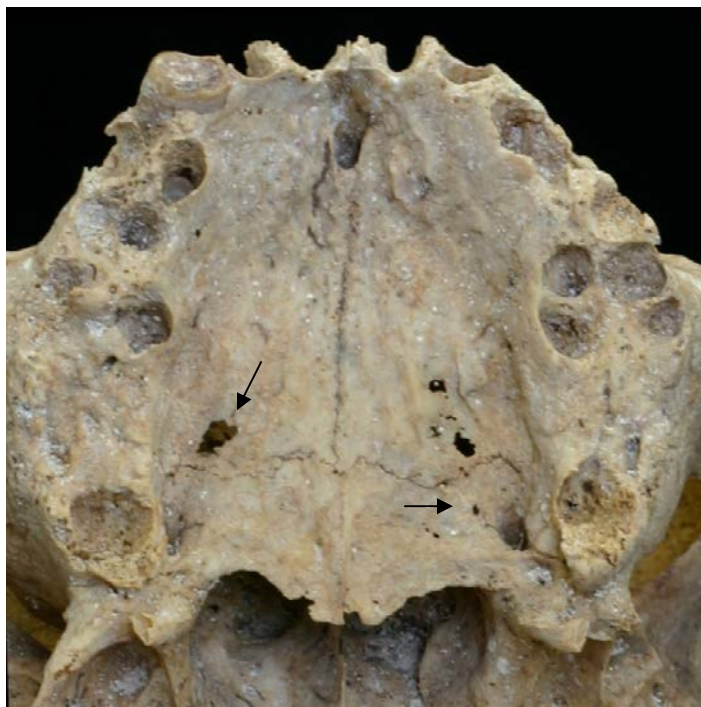

Figure 7.3: Burial 1 – Inferior view of maxilla and palate. Pitting or lesions on the posterior maxillae and palate (see scurvy discussion below).

Focal Bone Loss




Figure 7.4: Burial 1 – Anterior view of right scapula showing areas of focal bone loss.

There were several sites of focal bone loss, especially in areas where the cortical bone is thinnest: scapulae, clavicles, manubrium, innominates, and the posterior surfaces of the thoracic vertebra (Figure 7.4). Areas of focal bone loss were also apparent on the centra of several vertebrae, most notably L5 (Figure 7.5) and T3.

These areas of focal bone loss are distinctly different from cases of porotic hyperostosis and osteoporosis although they may have been exacerbated by the latter condition. Their primary cause is probably related to conditions of general illness which are discussed further at the end of this section and in Section VIII.



Figure 7.5 – Burial 1 - Inferior surface of the fifth lumbar vertebrae showing focal bone loss (posterior at the top of the image).

Osteoporosis

The long bone epiphyses and vertebrae have all started to show signs of diffuse bone loss (osteoporosis). Gradual bone loss in an older adult exacerbated by poor nutrition (Drezner 1995) resulted in a delicate spine and increased porosity on and around the articular surfaces (Figure 7.6).

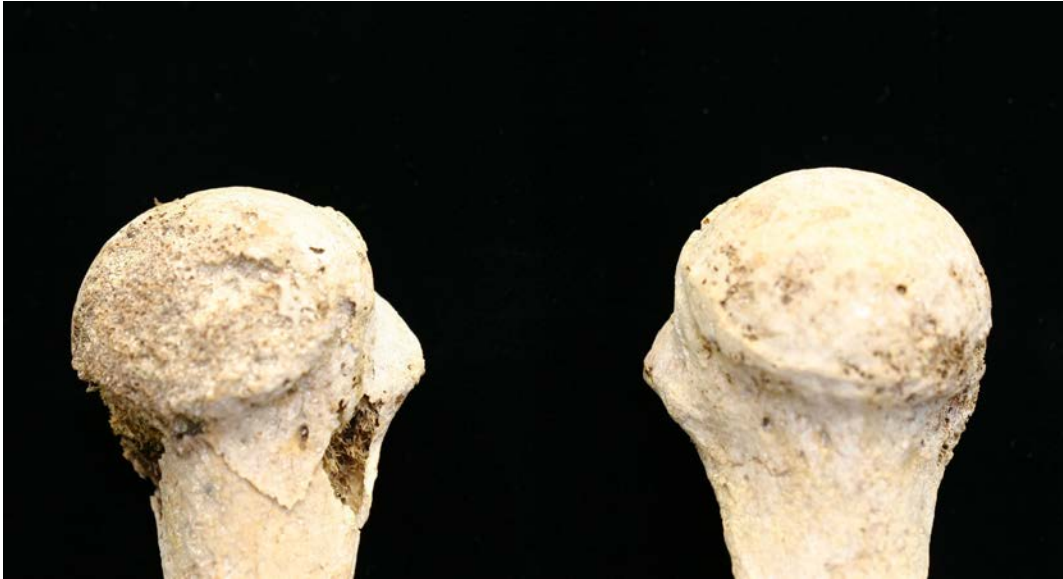

Figure 7.6: Burial 1 – Medial view of humeral heads, showing the extent of osteoporosis on the distal ends of long bones.

Infection

Periostitis

Skin lesions and inflammation associated with infection can affect the surface of the bone. Periostitis, the reaction on the bone surface, is either active (reactive woven bone) or healed (sclerotic) and can often be a combination of both. Areas of periostitis were noted on the long bones, however, observations for periostitis were compromised by the effects of a sandy matrix and weathering on the surface of the bone.

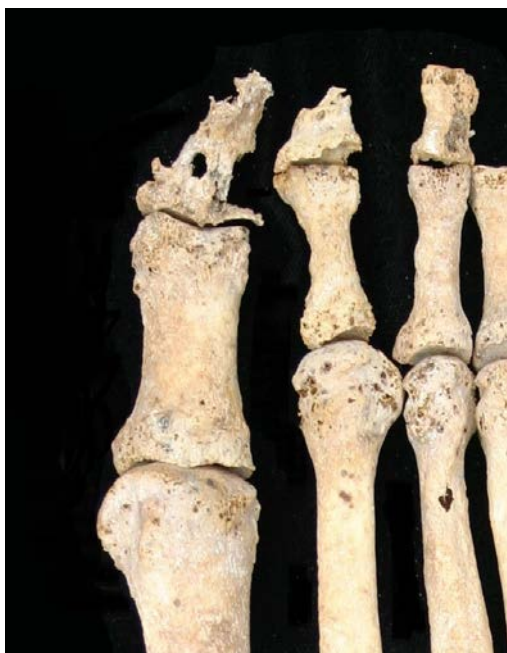

Figure 7.7: Burial 1 – Superior view of the right foot showing infection in distal phalanx.

One of the most severe infections occurred on the big toe of the right foot, resulting in diffuse bone loss and structural collapse of the distal phalanx (Figure 7.7).

Musculo-skeletal

Os Acromiale



Figure 7.8: Burial 1 – Right scapula posterior view, close-up of acromion process, showing os acromiale (non-fusion).

This individual had unilateral os acromiale on the right scapula, a condition whereby the acromion process of the scapula does not fuse as a result of “tearing of the rotator cuff due to continued and heavy loading” on that arm (Capasso et al 1999:48). Fusion of the acromion can take place anywhere between the ages of 16 and 25 years old (Bass 1995:126) and because the fusion never occurred, it is likely this man was engaged in heavy labor at a young age. Further evidence for extensive use of the right arm becomes more evident in the section on muscular hypertrophies.

Non-Fusion

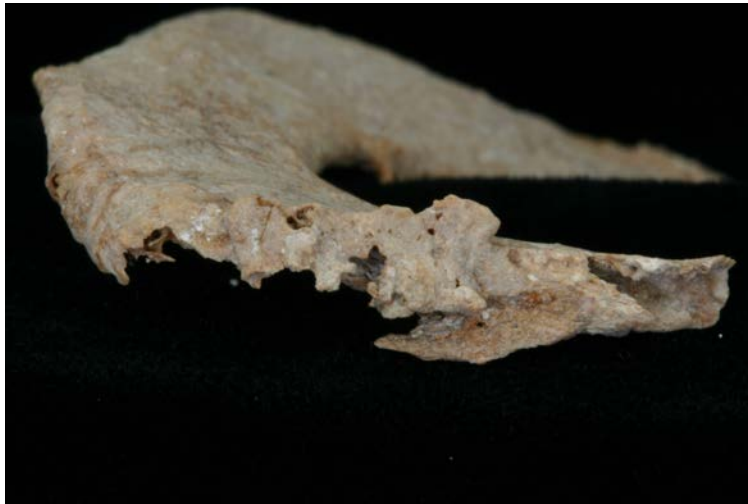

Figure 7.9: Burial 1 – Left 1st Rib medial view, showing non-fusion of the rib head.

Similar muscle strain on the left hand side chest muscles also contributed to a non-fusion of the rib head on the 1st rib. The fusion of the rib head with the body occurs sometime in the late teens to early adulthood (White 1991).

Fractures



Figure 7.10: Burial 1 – Left 2nd Rib superior view, showing area of a healed fracture.

One healed fracture was observed with Burial 1 on his left 2nd rib (Figure 7.10). The rib broke midway through the sternal body but was completely healed at the time of death. The fracture is completely healed and is no longer visible except for a noticeable area of bone apposition.

General Trauma / Morphological Variation

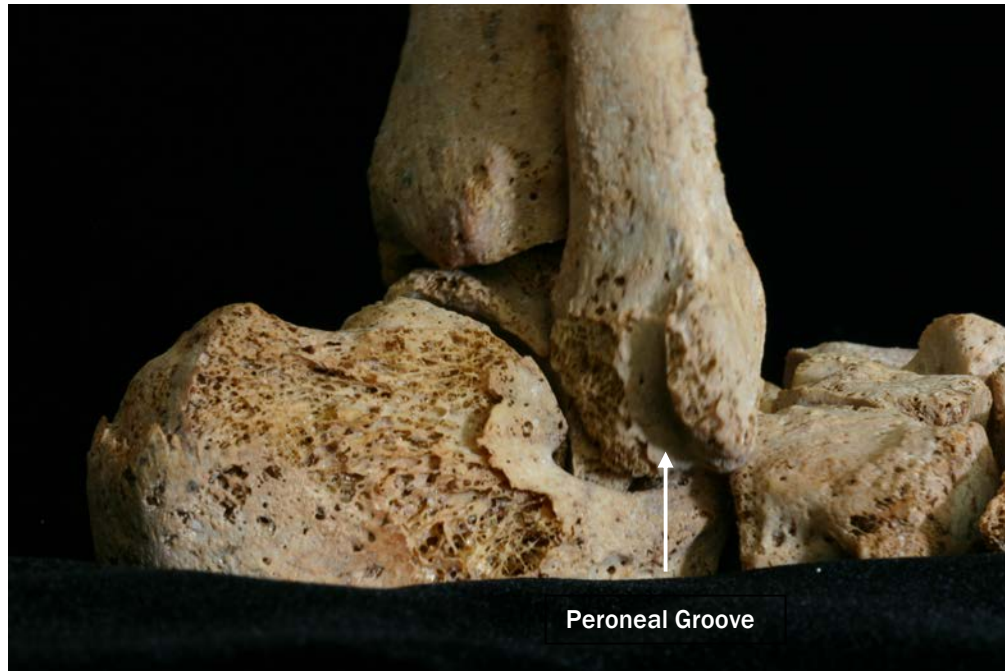

Figure 7.11: Burial 1 – Articulated right foot and ankle. Posterior / lateral view, showing groove and abnormal bone growth on the distal end of the right fibula.

Morphological changes to the distal end of the right fibula have resulted in the rounding of the lateral malleolus and the shortening of the right fibula, in comparison to the left, by 5 mm. There is an area of porous bone apposition on the lateral surfaces which define the peroneal groove (Figure 7.11). The peroneus longus and peroneus brevis muscles, which are responsible for plantar flexion and eversion of the foot, are attached at different locations along the fibula. At the lower end of the calf, the muscles end in tendons which pass over the lateral malleolus, through the peroneal groove, and end in the foot. Although there are no muscle attachments in this area, several ligaments connect the lateral malleolus to surrounding elements. The fibular attachment for the ligament that connects the medial surface of the distal fibula to the tibia, the interosseus ligament of tibiofibular syndesmosis, exhibits a pronounced rugosity on the right and may be related to the trauma discussed in this section.

Although it is not clear what conditions led to the change in ankle morphology, some form of trauma has taken place at the distal end of the fibula. The most distal end of the lateral malleolus could have fractured resulting in a noticeable change in length and an area of bone apposition. Trauma or work related conditions requiring

plantar flexion and eversion movement of the foot could have caused excessive strain on surrounding ligaments and muscles resulting in a muscular hypertrophy on the lateral malleolus. Or, a hematoma in surrounding tissues or inflammation of connective tissues in the area could also cause reactive bone growth and remodeling of the distal end. These possibilities will be discussed in more detail at the end of this section and in Section VIII.

Muscular Hypertrophies

Upper Body

Further asymmetry is seen in the significant size difference between the left and right mastoid processes. Evidence of mechanical stress using the sternocleidomastoid muscle is seen in the enlarged right mastoid and corresponding attachment on the clavicle. These hypertrophies and enthesopathies are considerably more severe on the right than the left. The unilateral use of this muscle can be attributed to tilting the head slightly up and rotating it in order to look over the left shoulder (Williams 1995:805) but could also be attributed to excessive strain on the right side of the neck. Apart from the osteoarthritis visible in the sternoclavicular joints, excessive stress on the right shoulder also caused the cartilage connecting the sternum and the right 1st rib to ossify.

The group of muscle attachments in the upper arm showing the most strenuous use is the pectoralis major, teres major and latissimus dorsi which work in conjunction to rotate the humerus medially and toward the center of the body (Williams 1995: 838). These hypertrophies and enthesopathies are slightly more severe on the right side and would be the result of this individual continually reaching across the body with either arm and meeting some resistance.

Both the knee and elbow joints have undergone the transition of a key ligament from tissue to bone. The ossification of these tissues is a result of strenuous overuse of the muscle, ligament or tendon in that area. The elbow joint pathology is significantly more severe as the ulnae have developed an extension of bone on the posterior surface of the proximal end (Figure 7.12). This area of the ulna, which is where the insertion for the biceps brachii is located, is attributed to “carrying heavy loads while the elbows are tightly flexed” (Larsen 2000:189). This action is also verified by the noted strenuous use of the supinator on the ulna which works with the biceps brachii (see below) for turning the palm anterior and lifting something with one’s elbows partially flexed (Williams 1995: 851). Activities associated with stress on the biceps brachii include woodcutting and blacksmithing (Capasso et al 1999:78).



Figure 7.12: Burial 1 – Medial view, proximal end of the left ulna, showing arthritic lipping on articular facets and ossification of connective tissues.

Lower Body

The patellar ligament (quadriceps tendon) which is an extension of the quadriceps femoris has ossified in a fashion similar to the enthesopathy seen in the elbow (Williams 1995: 700) (Figure 7.13). Quadriceps femoris is a grouping of four muscles (rectus femoris, vastus lateralis, vastus medialis and vastus intermedius). This muscle group works to extend the knee or extend the knee and hip simultaneously. The patella is laterally displaced when the knee is bent and the vastus medialis and vastus lateralis work to keep it centered. (Williams 1995: 873)

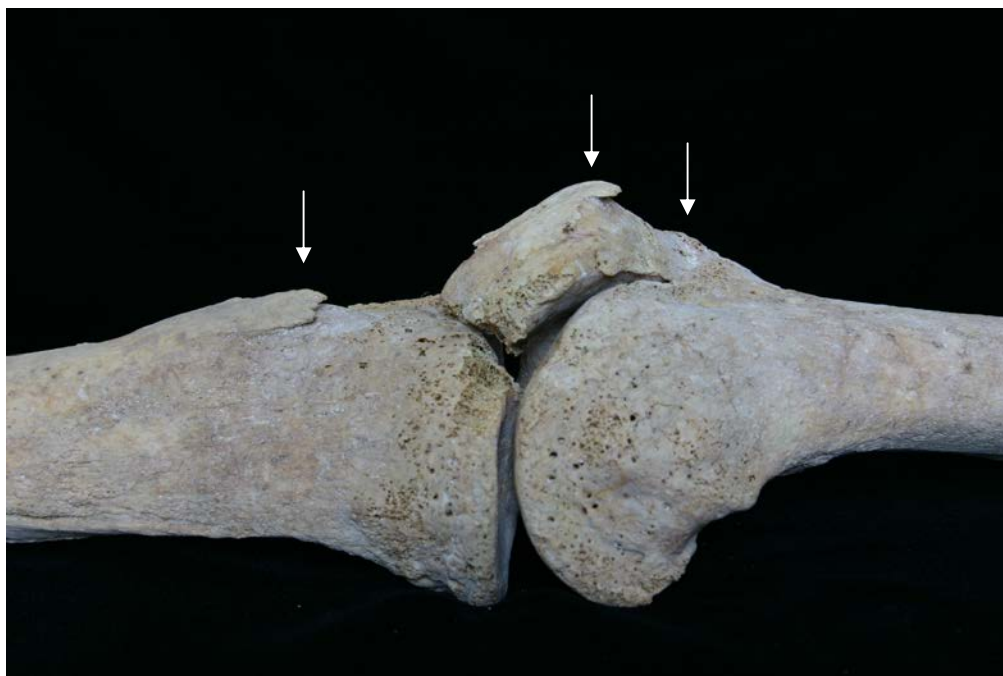

Figure 7.13: Burial 1 – Medial view of right knee joint showing ossification of connective tissues.

To some extent, these spicules of bone are also seen on the back of both feet where the Achilles tendon attaches to the calcaneus which is related to “excessive walking and running” (Larsen 2000:189) (Capasso et al 1999:139). The tendo calcaneus is also linked to the use of the soleus muscle whose attachments on both fibulae and tibiae have severe enthesopathies. (Williams 1995:886). These muscles and tendons work in conjunction to keep an individual steady on their feet in uneven terrain and have been attributed to carrying heavy loads on steep paths (Capasso et al 1999:122). In this case, the foot is usually in “partial plantar flexion” meaning that the heels are slightly off the ground while climbing, most likely contributing to the enthesopathies of the tendo calcaneus.

The femoral muscle attachments also substantiate this sort of continuous movement. The corresponding attachments for the soleus on the femur (lateral and medial gastrocnemius) just behind the knee have noticeable hypertrophies. The attachment for the adductor magnus, also known as the linea aspera and runs the entire length of the femur on the posterior surface, is extremely pronounced bilaterally but is more prominent on the right (Figure 7.14).

In conjunction with adjoining adductors (adductor longus and adductor brevis), the adductor magnus muscles are active during flexion and extension of the knee and hip. The combined use of gluteus medius and gluteus minimus serve to abduct the thigh and stabilize the hip when the alternate foot is lifted off the ground. Thus, these muscles are alternately active during walking but are not in a constant state of use (Williams 1995:877). Given the unilateral severity of these attachments, it is more likely that the hypertrophies are attributed to a work related movement rather than walking (Figure 7.14).

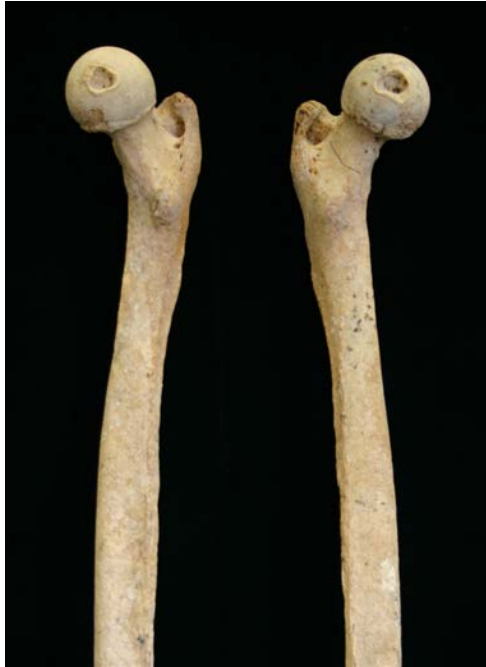

Figure 7.14: Burial 1 – Medial view of both femora showing extent of muscular hypertrophies on the right femur (to the left of the image).

Osteoarthritis

Osteoarthritis, a product of biomechanical stress and physical activity (Larsen 2000) has manifested in every major articular joint for Burial 1 with varying severity.

The clavicles, scapulae and humeri on both the left and right exhibit some arthritic lipping and porosity at the shoulder joint and the humeri, ulnae and radii at the elbow joint. The most severe case of osteoarthritis is visible in his right wrist which started to develop spicules of bone around the distal end of the radius and ulna bordering on osteoarthritic fusion of the wrist (Figure 7.15). Similar unilaterally severe arthritic changes are also visible in the bones (carpals) of the right hand.

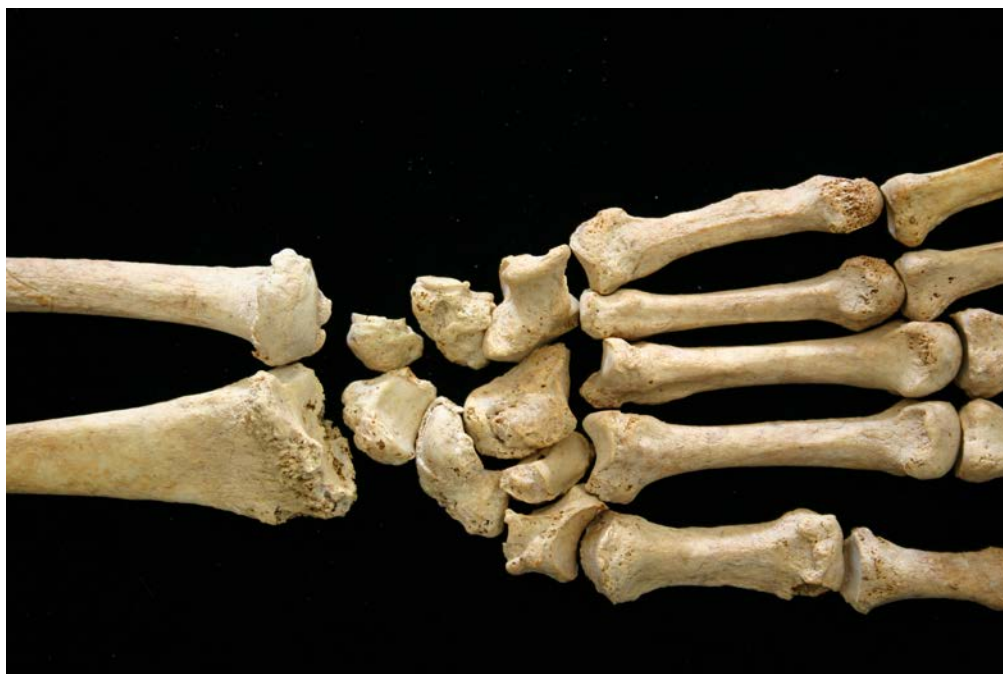

Figure 7.15: Burial 1 – Palmar / anterior view of right wrist showing severity of osteoarthritis including lipping and spiculation.

The hip, knee and ankle joints also have incidences of arthritic lipping but the use of the joints is more clearly reflected in the muscular hypertrophies. More pronounced arthritic lipping on the left temporo-mandibular joint could be a byproduct of both occupational wear and an increasing reliance on the left teeth, which remained in better condition than his right teeth as he was aging.

The spinal column has significant and clear evidence of osteoarthritis. The cervical vertebrae in the neck all exhibit lipping on the centrum. Both superior and inferior articular facets on the thoracic and lumbar vertebrae exhibit arthritic lipping with spiculation. Beginning with T3, the superior articular facets on the thoracic vertebrae developed spicules that extended superiorly to nearly enclose the inferior articular facet of the adjoining vertebra. Osteophytosis, a condition precipitated by load bearing on the head and neck (Capasso 1999: 40), is visible on L3 and L4. In addition, articular facets of the vertebrae in the neck show an unusual pattern of facet extension. C1 and C2 have larger articular facets on the right side and C3 through C6 have larger facets on the left consistent with continual turning of the head to the left.

Burial 1 Summary

There is a considerable amount of asymmetry throughout this older man's body. The vertebrae, as midline elements, are equally as asymmetrical suggesting that the work he was doing required different ranges of motion on each side. Reviewing all of the pathologies, there are some areas of note, particularly the right shoulder, the right wrist, right thigh, both elbows and both knees indicating persistently

repetitive motions as well as lifting and carrying heavy loads. In addition, many of the muscles that he used extensively work to stabilize the body.

In addition, there are several indicators of a systemic infection having occurred during this man's lifetime.

Preliminary discussion of infectious disease and nutritional deficiency

Infection, disease and nutritional deficiency can result in similar skeletal manifestations. The pathologies discussed above may be indicative of tuberculosis and/ or scurvy. The following discussion begins to explore these potential interpretations for Burial 1.

Tuberculosis

Tuberculosis is an infectious disease caused by various species within the "*Mycobacterium tuberculosis* complex" differentially infecting humans and animals (Roberts and Buikstra 2003:4). Airborne "droplets" are conveyed by an infected human or animal (for example, through coughing or sneezing) to another person's respiratory system or can be contracted in the gastrointestinal system by coming in contact with infected animal products (Roberts and Buikstra 2003:5). Roberts and Buikstra (2003) cite the Seaton et al. 1989 study which suggests that prolonged exposure to an infected person(s) or animal(s) is necessary for someone to become infected. Consistent with this assertion, overcrowding and/ or contact with animals are usually associated with tuberculosis.

While the primary site of infection takes place in the lungs or gastrointestinally, lungs are the most common origin. Tuberculosis can lay dormant, not entering the bloodstream or spreading, for years after the primary infection (Ortner and Putschar 1985). Spread of the infection can be hampered or expedited depending on levels of nutritional adequacy and immunological strength of the individual (Ortner and Putschar 1985; Roberts and Buikstra 2003).

Osteological manifestations indicating tuberculosis are usually associated with focal bone loss and collapse of vertebral bodies, usually in the thoracic vertebrae. This individual has several indicators that suggest tuberculosis infection. Focal bone loss was present circumferentially on the sides of the vertebral bodies in the spine and on the inferior and superior surfaces of the vertebral bodies of T1-T3 and T6 (see Figure 7.5). Evidence of inflammatory response in the ribs and diffuse bone loss in the sternum are consistent with observations of bone tuberculosis infection. Though age is a confounding factor in this interpretation, the extant osteoporosis and degenerative joint activity throughout the skeleton, may also be related to tuberculosis. When tuberculosis travels through the bloodstream, infection can enter bone marrow, particularly affecting the epiphyses and metaphyses of long bones. The trauma and bone formation in the distal end of the right fibula and the shorter length of this element may relate to tuberculosis infection during

development (see scurvy discussion). If a long bone epiphysis is severely damaged due to tuberculosis, the infection “will leave a growth deficit and/or deformity” in a developing person (Ortner and Putschar 1985:144).

Scurvy

Pitting on the cranial vault and eye orbits, if coupled with expansion of the diploe, indicates an anemic reaction due to dietary iron deficiency, reaction to a parasite or disease. Pitting on the cranial, facial and mandible bones (particularly on the greater wing of the sphenoid) without evidence of diplotic expansion, is likely related to scurvy caused by vitamin C deficiency (Melikan and Waldron 2003; Ortner et al 2001; Ortner et al 1999; Ortner and Erikson 1997). Ortner and Erikson (1997) prefer the operational term “porous bone” to indicate “chronic inflammation” versus porotic hyperostosis or pitting related to anemia and evidenced with expansion of the diploe. The distribution pattern of pitting in the facial elements, specifically in the greater wing of the sphenoid, palate, and posterior portion of the inferior maxillae, are indicative of scurvy. However, cross-sectioning or radiographic analysis would be necessary to confirm absence of diplotic expansion. Much of the cranial pitting and periostitis displayed in this individual has healed, indicating that these reactions may have been chronic. Alveolar resorption, periodontal disease, tooth loss, periostitis and lesions/focal bone loss on the scapulae suggest scurvy that continued or worsened in the latter part of his life due to factors such as aging, diet, infection and mechanical stress. (See Figures 7.3, 7.4 and 7.16)

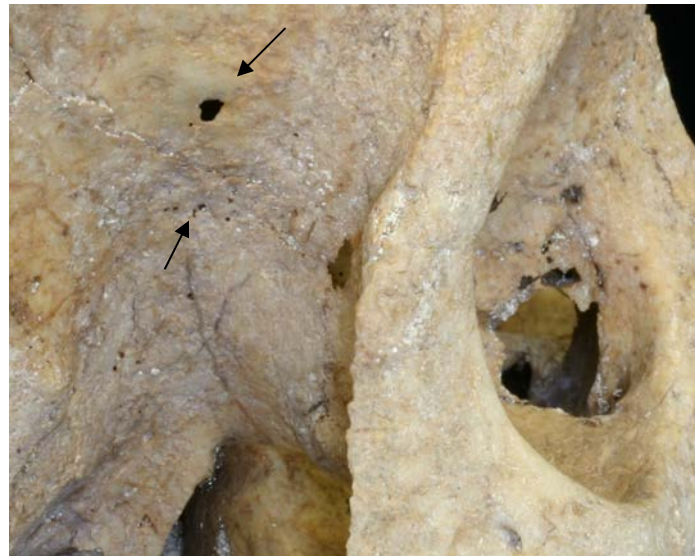

Figure 7.16: Burial 1 – Lateral view of cranium (anterior to the right of the image). Pitting or lesions on the greater wing of the sphenoid and adjacent frontal bone associated with scurvy

Burial 2

Developmental / General Stress Indicators

Suture Asymmetry



Figure 7.17 and Figure 7.18: Burial 2 – superior (to the left) and posterior (to the right) images of the cranium showing cranial suture asymmetry.

As mentioned in the section on aging, the coronal and lambdoid sutures show signs of asymmetry (Figures 7.17 and 7.18). Both the coronal and lambdoid sutures on the right side tend to be more complicated and closed and less complicated and open on the left. The variation in suture closure may be an indicator of either nutritional or occupational stress at a young age affecting the physiological development of the cranium. Axial loading with a right side bias should be considered as a possible contributor to this pathology.

Hypoplasia and Hypocalcification

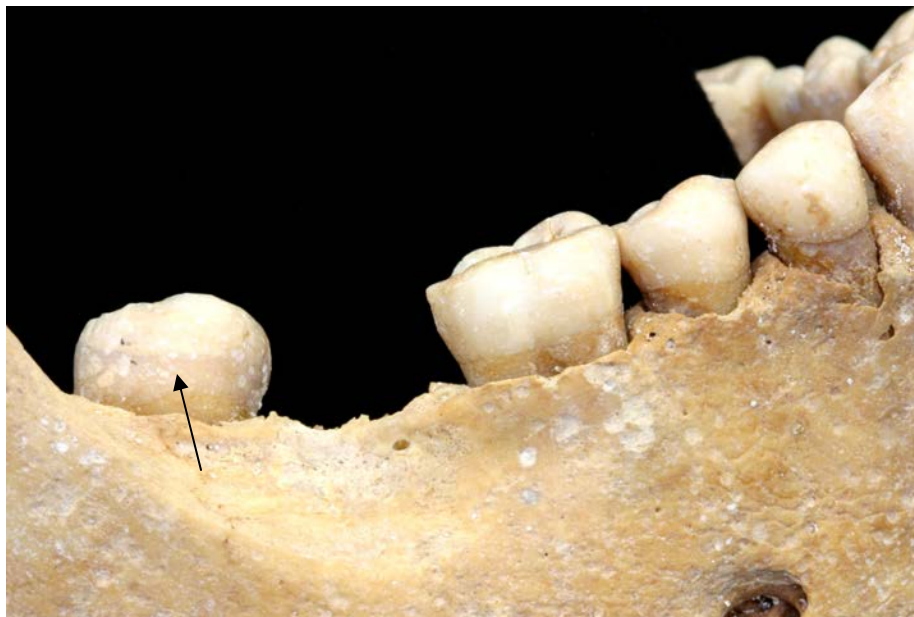

Figure 7.19: Burial 2 – Right lateral view of mandible showing hypoplasia on RM₃.

During dental growth at a young age, episodes of stress caused by illness or diet, disrupt normal enamel development. The interruptions in normal development result in either a visible transverse line across the developing tooth (hypoplastic lines) or one or a series of transverse pits across the tooth (hypoplastic pits).

Hypoplastic lines and hypocalcification are visible on the mandibular molars and canines (Figure 7.19). Enamel defects were not observable on the medial and lateral incisors due to post-mortem damage to the teeth.

Pitting/ Porous Bone

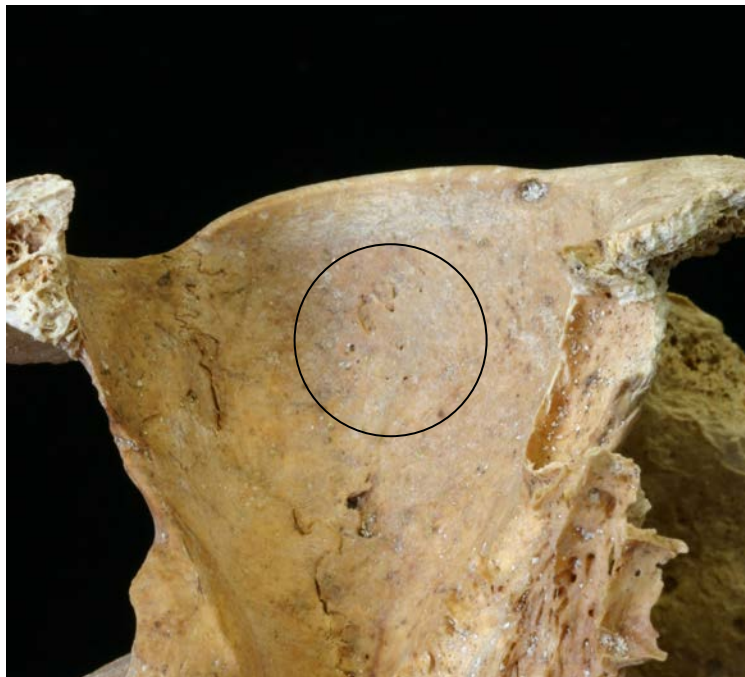


Figure 7.20: Burial 2 – Inferior view of right eye orbit showing pitting

Evidence of both healed and unhealed pitting is visible on the sphenoid (specifically the greater wing) parietals, occipital, temporals and maxilla with the most severe case visible on the inferior surface of the eye orbits (although fragmentation did not allow complete observation) (Figure 7.20). As with Burial 1, the distribution of the pitting in the absence of diplotic expansion suggests disease related reaction and possible scurvy.

Diet / Nutrition

Carious Lesion

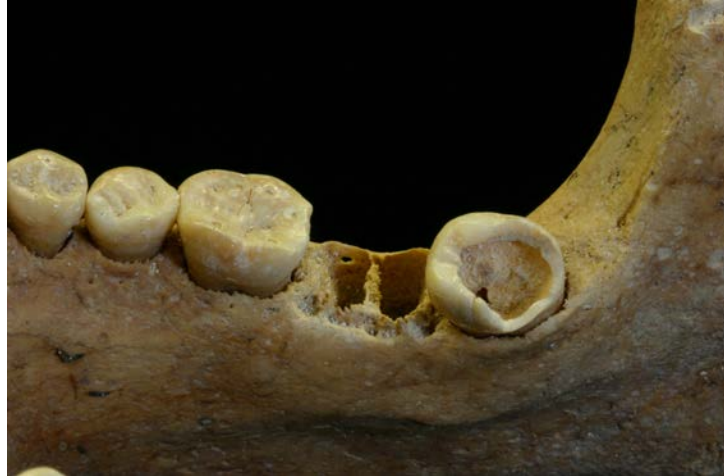

Figure 7.21: Burial 2 – Medial view of mandible showing fractured RM₃ exacerbated by a carious lesion. Note onset of remodeling in socket for RM₂.

The right mandibular third molar has an open fracture along the occlusal surface (Figure 7.21). This break could have been perimortem or occurred during excavation, but it is clear that the tooth had been weakened by a carious lesion prior to the fracture. Given the young age of the woman and the fact that the third molar is the last tooth to erupt, the rapid development of such a carious lesion may have been exacerbated by a diet high in starch or sugar.

Periodontal Disease

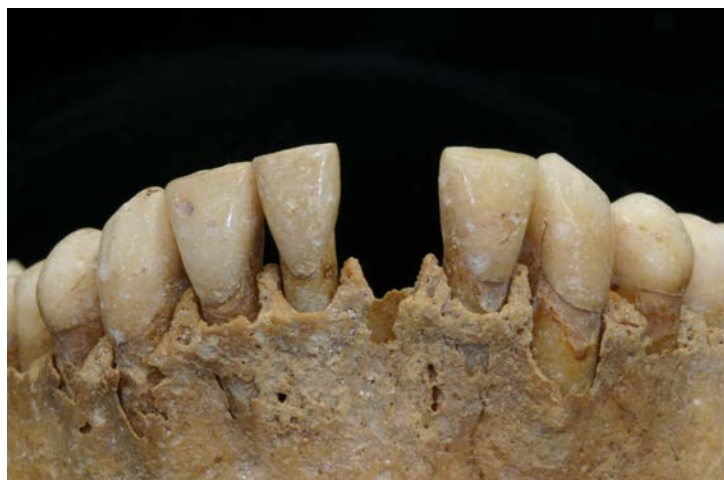

Figure 7.22: Burial 2 – Anterior view of mandible showing onset of periodontal disease.

The onset of periodontal disease is evident primarily in the anterior mandibular teeth. The alveolar bone has slightly receded and there is evidence of root exposure (Figure 7.22).

Bilateral Tooth Loss

Both of the mandibular second molars were absent for the young woman. The alveolar region on the left lingual surface shows the onset of an abscess and some signs of healing. The socket for the molar on the right exhibits early signs of remodeling that eventually leads to resorption. Both of these indicators suggest that the teeth were lost antemortem and were likely voluntarily removed not long before she died. Bilateral loss of the same tooth was also common among an archaeological population of enslaved Africans and Afro-Caribbeans in Barbados (Handler and Corruccini 1983). The authors believe this is a clear indication of voluntary intervention and removal of “painful or diseased teeth” (1983:83).

Exostoses

Exostoses (spicules of bone) of the external auditory meatus and the inferior aspect of the temporals were observed bilaterally and “may be associated with inflammation and infections of the ear, which are often associated with swimming and exposure to cold water (see Hutchinson et al. 1997)” (Blakey and Barrett 2004).

Tooth Wear

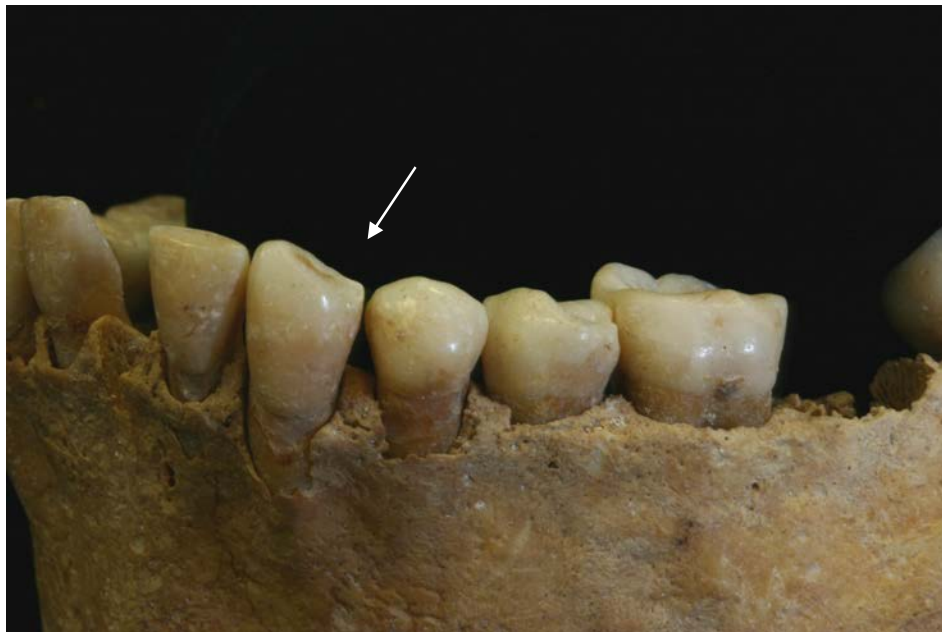


Figure 7.23: Burial 2 – Left lateral view of mandible showing wear facet on left canine.

This woman also has visible wear facets on the mesial occlusal surface of both the right and left mandibular canine (Figure 7.23). An accompanying facet cannot be seen on the adjacent first premolars although they are set a bit lower than the canine and the maxillary canines are not present for observation. The wear is similar to, what is commonly called, a “pipe notch” or “pipe-smoker’s wear” or an area of the teeth that develops a wear pattern from the consistent gripping of a pipe stem in the same spot over time. Handler and Corruccini’s study of a seventeenth and eighteenth century archaeological population of enslaved men, women and children on Barbados indicate that the most common locations for pipe facets are either between the canine and lateral incisors or between the canine and first premolars (1983). Given the absence of wear facets on the first premolar in this case, the facet may have been created by occlusion.

In addition, uneven wear on the molars indicated that this individual had a slight underbite.

Musculo-skeletal

Muscular Hypertrophies

Further asymmetry is seen in the significant size difference between the left and right mastoid processes. The larger right mastoid process is likely due to a muscular hypertrophy of the sternocleidomastoid and is a result of a strain on the right shoulder or looking consistently over the left shoulder. The activity causing the hypertrophy is likely similar to the older male from Burial 1.

Burial 2 Summary

This young woman has several indicators of considerable developmental stress at a young age, including hypoplasia, cranial suture asymmetry and pitting in the eye orbit. In addition, the asymmetrical development of the sutures and the enlarged right mastoid may be the result of strenuous labor affecting the body unilaterally. The onset of periodontal disease and a carious lesion on the right third molar at a young age are the result of a diet high in starch and sugars.

Despite the difference in age and sex profiles, the pathologies observed for Burial 2 (a young woman) are strikingly similar to those observed for Burial 1 (an older man) in different stages. Both exhibit a unilateral use of the sternocleidomastoid on the right side and the early onset of carious lesions and periodontal disease.

Section VIII

Biographical Interpretation

The purpose of the following section is to interpret the skeletal analysis of Burial 1 and Burial 2 within their historical, archaeological and socio-economic context. Contextualizing the skeletal analysis within eighteenth century Guana provides insight into how the lives of this man and woman fit into the history of this island as a sugar plantation reliant on enslaved labor. Both burials were located within a larger cemetery near the archaeological foundation of a house used by the enslaved Africans and their descendents in Guana. Artifacts date the burials within the eighteenth century (see sections II and III).

Socio-economic Context

Within the British Leeward islands during the eighteenth century, sugar cultivation was dependent upon and directly related to the expansion of enslaved labor, importation of captive Africans, and a plantation labor system (Goveia 1965:104). Planting was done during the rainy season sugar was processed during the dry season between January and June. (Goodwin 1987:42-43).

The work involved in sugar cultivation in the Leeward Islands was made particularly strenuous by slaveholders' use of human labor rather than cattle. During the agricultural season the cane field was prepared and fertilized, requiring one hole to be dug for each plant, a practice known as holing. Holing, according to Goveia, "was universally agreed to be one of the most laborious tasks of cultivation that the West Indian slaves had to perform" and was practiced in place of using a cattle-drawn plough. Rather than staking cattle in fields to fertilize, enslaved workers carried manure "in baskets on their heads" (Goveia 1965:119).

Each person had to dig approximately 60 and 100 holes per day per in order to complete preparing the field by late October and begin planting. The final agricultural task was to harvest the cane. At harvest time, workers cut the ripe cane by hand with knives called bills. The upper 12 inches of the stalk was cut first and set aside. The rest of the cane was cut close to the ground and sent to the mill for crushing. As they proceeded, the workers stripped the dry leaves from the canes. The stripped leaves were brought to the factory and used as fuel for the boiling house (Dunn 1973[1972]:192; Goodwin 1987:64-66).

Once the sugar cane had been cut, the stalks were immediately brought to the mill where they were crushed and the juice extracted. The work in and around the crushing mill was extremely dangerous. Hands and clothing were very susceptible to getting caught in between the mill's turning rollers, as Edward Littleton (1689) describes, "If a Mill-feeder be catch't by the finger, his whole body is drawn in, and he is squeez'd to pieces (in Dunn 1972[1973]:192)."




Figure 8.1: Sugar Mill (Diderot 1762, vol. 1)

From the crushing mill, the extracted juice was transported, via a gutter or pipe, into an adjacent boiling house for processing. After heating the juice in the first copper, any impurities that rose to the surface were skimmed off (see image below) and the juice is transferred to a second slightly smaller copper using a long-handled ladle. The boiling juice is transferred from copper to copper by this method until finally it is placed in the smallest copper, called the strike pan. From the strike pan, the juice is transferred into cooling tanks where the crystallization process takes place (Clement 1995:107-111).




Figure 8.2: Boiling House (Diderot 1762, vol.1)

The work in the boiling house was even more dangerous than in the mill due to the extreme heat and smell produced by the boiling sugar. The boiling sugar also posed a significant physical threat. Littleton once again remarked, If a Boyler get any part into the scalding sugar, its ticks like Glew, or Birdlime, and 'tis hard to save either Limb or Life (in Dunn 1972:194). The remains within Burial 1 and Burial 2 reflect the complexity of living within the eighteenth century Atlantic world. Their bodies bear the physical evidence of strenuous labor required of them as enslaved laborers on a sugar plantation.

Interpretation

Burial 1

Pitting in the sphenoid, eye orbits, nasal bones, zygomatic bones, maxillae, palate and alveolar processes, extensive alveolar resorption, dental loss and lesions in the scapulae combined with a high frequency of remodeled inflammatory response in the post cranial skeleton indicate that this man may have experienced scurvy. Focal and diffuse bone loss in the spine, sternum and ribs and severe osteoporosis indicate chronic tuberculosis infection. Trauma in the distal end of the right fibula may be related to either of these pathologies or neither (see Section VII).

A diet lacking ascorbic acid (vitamin C), found in fresh fruit and vegetables, causes scurvy, a disease with a variety of symptoms including periodontal disease, bleeding of the gums and hemorrhaging at sites of vascular trauma from mechanical stress. Vitamin C is crucial to the development of connective tissue, and when absent in the diet, connective tissue and vascular strength are greatly compromised, resulting in bleeding when engaging in strenuous activity and even in ordinary actions, such as chewing and moving the eye muscles. (Ortner and Eriksen 1997; see also Melikan and Waldron 2003; Ortner et al 2001; Ortner et al 1999). An inflammatory response can stimulate bone reaction resulting in “reactive” woven bone or, when healed, “sclerotic” lamellar bone (Buikstra and Ubelaker 1994). During the developmental years, stimulation of bone growth is also likely to occur in the metaphyses of the lower limbs at the site of trauma and inflammation (Ortner and Eriksen 1997:213). Porous bone can occur as a result of hyper-vascularization as well as the formation of hypertrophic new bone where trauma or hemorrhaging occurred (ibid). Historically, sailors have suffered from scurvy during their extended time at sea due to the poor quality of diet lacking fresh vegetables and fruit. Scurvy has also been documented within enslaved populations generally, and specifically among enslaved field workers in the British Leeward Islands of the eighteenth century (Goveia 1965:234).

This individual had unusual and pronounced bone formation on the distal end of the right fibula. The location of this formation, the slightly shorter length of the right fibula compared with the left fibula (see section VII), and the porous quality of the bone formation support the possibility that trauma resulting from scurvy or tuberculosis during fusion (between the ages of 14 and 20 years). This developmental period is concurrent with the ages at which the acromion process

and first rib should have fused. Archival records containing the ages of enslaved Africans in the Leeward Islands in the seventeenth and eighteenth centuries show a prevalence of men in adolescence to early adulthood (Dunn 1973 [1972]:318). Within the historical and socio-political context of this man's life, the fibula trauma at the metaphysis, and the failure of the left rib and the right acromion process to fuse, may represent the period of forced migration and strenuous labor upon entering the Americas during adolescence to early adulthood.

There is no evidence of enamel hypoplasia in this individual's remaining teeth. The canine and the third molar are present, but offer no evidence of general stress during early childhood (6 months to 6.5 years old) or in later childhood and adolescence. The years of development represented by the dentition also support onset of adverse nutritional, disease, and possibly contributing mechanical stressors in late adolescence and early adulthood.

Conditions of enslavement such as poor diet and strenuous labor are evident within this individual. Historical records of diet indicate a large reliance on starchy foods such as flour, corn, peas, yams, potatoes and sometimes sugar and rum, salted cod fish and supplemental food raised on provision grounds (Dunn 1973 [1972]: 278; Goveia 1965: 135-137). Beyond the possibility of scurvy in his earlier years, the high degree of alveolar resorption, dental loss, caries and abscessing is consistent with a diet high in sugars and starches. Furthermore, this person died later in life and may have had a poorer diet in his later years. Documentary records provide reference to slaveholders' value of younger laborers, while often subjecting men and women who survived beyond the ages of 40 to poorer living conditions and diet (Dunn 1973 [1972]:320). Decreased bone density, arthritis and vertebral pathology are common in older individuals. However, the severity and distribution of osteoporosis and focal bone loss within this older man may also be related to tuberculosis, intensified by heavy labor during his lifetime (see section VII).

Differing severities observed in arthritic lipping and ligament and muscle attachments between left and right sides of this man's body are consistent with activity specifically related to cane cultivation and harvesting. A larger mastoid process on his right side and the enthesopathy on his right clavicle are evidence of severe strain or use of his right sternocleidomastoid muscle (see Figure 8.3 and labor descriptions below).




Figure 8.3: Man planting cane in sugar cane field in twentieth century Puerto Rico (Mintz 1960).



Figure 8.4: Workers in a sugar cane field in twentieth century Puerto Rico (Mintz 1960).

We are continuing to examine the following distribution of stress indicators for evidence of work involving a twisting motion of the neck and upper body: alternating lateralization of enlarged articular facets in cervical vertebra C1 – C7, alternating right and left orientation of cervical and thoracic vertebrae spinous processes (see Figure 8.5) os acromiale in the right scapula, non-fusion of the left first rib head and a fracture in the right first rib.

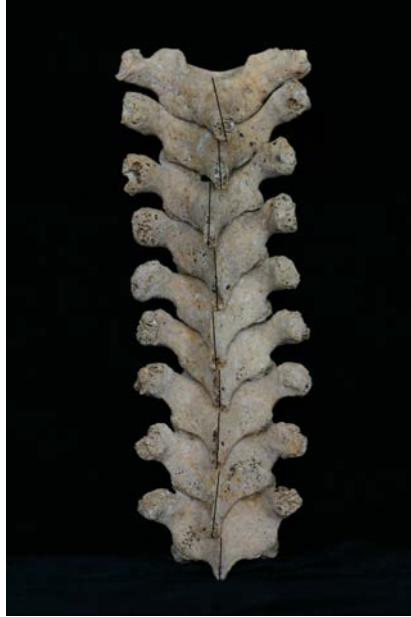

Figure 8.5: Alternating right and left orientation of cervical and thoracic vertebrae spinous processes in Burial 1 (lines indicate orientation of spinous processes).

This man had been engaged in heavy labor at least as early as adolescence or early adulthood (see Rankin Hill 1997 for a discussion on os acromiale, labor and development). Spicules on the wrist, elbow and knee joints result from repeated or sustained flexion of these joints. The calcaneus bone shows evidence of sustained flexion of the ankle with weight bearing on the foot. Lower limb attachments may also have been affected by the terrain, requiring a person to walk on steep inclines (see Section III).



Figure 8.6: Worker using a hoe for cane cultivation in twentieth century Puerto Rico (Mintz 1960).

An observer of migrant cane cutters on sugar plantations in late twentieth century Florida described their movements as:

stepping forward with the foot on the side of one's cutting hand (keeping the other foot back and clear of the blade on its follow-through); bending over and wrapping an arm around a bunch of stalks and raising the blade up over the shoulder and bringing it down hard across one's body to the field, striking the cane at the base of the stalk; shaving the tops from the stalks with short, flicking strokes...(Wilkinson 1989:52)

One cane cutter described his work as "Grilling, backbreaking, strenuous, and rough. The bending is [a] tremendous strain on your back, your shoulders twisting left, twisting right, bending up and down, lifting." (Wilkinson 1989:118)

Muscle and ligament attachments of the arms and legs show that this person engaged in heavy lifting and pulling. Evidence of infection, healed and active, was present throughout this individual's upper and lower body, but was most severe in his leg bones and at the sites of muscle attachments. The big toe on his right foot had evidence of very severe infection (see section VII).

The variety of activities or labor this person may have engaged in during his lifetime is not limited to the description above. However, the historical-archaeological context and the skeletal indicators for this individual suggest that his daily activity required bending, heavy lifting and extensive use of his shoulder, arm and leg muscles in a pattern consistent with cane cultivation and harvesting. Furthermore, the severity of his arthritis, vertebral pathology, hypertrophies and enthesopathies suggest that he had been working strenuously for many years prior to and up until his death.

Burial 2

This young woman's dentition provides a record of her general health during childhood through disruption in her enamel formation. Enamel (being acellular) does not remodel like bone and, therefore, provides a permanent record of health during the period of enamel development. Hypoplastic lines on this woman's incisors, canines and molars indicate an early onset and continuation of generalized stress, such as malnutrition or illness, throughout her adolescence. The earliest developing permanent teeth are the central incisors, which begin forming near six months of age, continuing enamel formation until the age of 3.5 years. Canine enamel develops between six months and approximately 6.5 years. The latest developing teeth, the third molars begin forming at age 9, continuing until approximately 16 years of age.

Using the method developed by Blakey (1994) and Goodman et al. (1980), the crown height measurement, the tooth-specific age range when enamel develops,

and the hypoplastic band measurements were used to assess the ages at which physiological stress and enamel disruption occurred. Hypoplastic bands in the canine indicate stress episodes during the approximate ages of 5.5, 6, and 7.5 years old. The right third molar displayed the most severe hypoplasia and indicates a stress episode between the approximate ages of 13 and 14 years, lasting for approximately one year.

Burials 1 and 2 are both missing second molars. All four second molars are missing in Burial 1 with complete alveolar resorption. Burial 2 is missing the mandibular second molars and shows evidence of the beginning stages of remodeling. Although Burial 1 experienced a great deal of dental attrition, the bilateral absence of the second molar in both burials may indicate practices of dentistry (as suggested by similar observation in Barbados) to remove pressure from encroaching third molars (Handler and Corruccini 1983).

Similar to the pitting patterns of Burial 1, this young woman displayed pitting or porosity in the greater wing of the sphenoid, maxilla, cranial vault and eye orbits in the absence of diplotic expansion. She may have experienced scurvy earlier in life, though how much earlier and the severity of the disease is not identifiable due to the absence of post-cranial elements. Fragmentation of the skull and absence of post-cranial elements does not allow for further observation as to the extent of pitting or presence of inflammatory responses.



Figure 8.7: Enslaved African woman carrying food using axial loading.

As observed in Burial 1, the mastoid on the right side of Burial 2 is larger than her left. The absence of post cranial elements prohibits comparison of the right clavicles. The suture patterns and fusion are asymmetrical and may be related to

mechanical stress or pressure to the head, such as axial loading. As in the image above, carrying loads or items on the head was a practice engaged in by African women in the Americas.

Women were often part of the gang labor system used in West Indian sugar plantations, performing the most arduous field labor along with men (Bush 1990:34-40). According to Bernard Moitt (2004:6), women - though often employed in the mills - "outnumbered men in the field gangs and did proportionately more labor than men." Within this context, it is more likely that this young woman worked in the cane field or in the sugar mills than in domestic service. Given the incompleteness of her remains, further interpretation is not possible.

Section IX Conclusion

The skeletal remains of a middle-aged man (Burial 1) and young woman (Burial 2) from Guana were found to have been exposed to infectious disease and nutritional deficiencies. Pathology indicators in the most observable individual (Burial 1) were consistent with tuberculosis and scurvy, the specificity of which we offer as tentative conclusions until more is known about the population and its history. The evidence of biomechanical stresses of physical labor is quite profound and includes extensive muscle attachment hypertrophy, os acromiale, and degenerative joint disease. In these respects these individuals' skeletons are similar to those from other remains of enslaved Africans in the Americas. They were highly stressed, but we currently have no way of knowing how representative of the Guana population these two individuals may have been since no statistical generalizations can be made from such a small sample.

We believe, however, that the observable pattern of stress indicators in Burial 1 may be hypothesized as a skeletal model for the purpose of identifying a sugar cane worker. The evidence of biomechanical stress, especially, is remarkably consistent with what one should expect under the demands of sugar cane agriculture, and even Burial 2's cranium bears consistencies with the observed pattern in the cranial and post-cranial skeleton of Burial 1. Overall, the pattern consists of the following criteria which Burial 1 embodies:

1) General, severe rugosity of the skeleton indicative of the historically documented extreme arduousness of sugar cane labor.

In Burial 1 such indicators include hypertrophies of the linea aspera and knee attachments for the triceps femorii, attachments for the biceps brachii of the ulna, and attachments for pectoralis and other humeral musculature.

2) Extreme asymmetry or lateralization in which the individuals' handed side (the right side in most cases) shows markedly more evidence of biomechanical stress than does the other side of the body, extending from head to foot. This lateralization is consistent with the constant use of a machete involving muscles and joints in one arm and shoulder as well as bending and twisting, and the extensive use of the foot on the same side for planting with a shovel.

In Burial 1 such indicators include the right mastoid process of the skull, os acromiale of the right shoulder joint, arthritis of the right elbow and of the right wrist, as well as slightly greater enlargement of the right linea aspera than of the left, and the possible fracture and hypertrophy of the right foot related to the action of the peroneal muscle.

3) Evidence of strain from repetitive twisting and bending.

In Burial 1 elements of the axial skeleton, especially the vertebrae, show alternating effects of joint degeneration and muscular strain to the left and right side.

4) Non-biomechanical pathologies such as extensive caries from eating sugar cane and nutritional deficiencies associated with regimes of plantation slavery.

In Burial 1 evidence of infectious disease and nutritional deficiencies are consistent with findings of highly stressed enslaved populations in both plantation and urban settings.

When these criteria are observed together in temporal and spatial contexts in which human populations were exposed to sugar cane labor, the patterns plausibly identify sugar cane workers. Studies of such a pattern do not yet appear in the literature, although one of us (M. Blakey) has observed commingled remains from a 19th century plantation of sugar cane workers (remains from the Kenner and Kugler cemeteries studied by Yakubic et al. (1986) at the Bonnet Carre' Spillway near New Orleans, Louisiana) that are consistent with the first criterion mentioned above. We are proposing these criteria, as observed in Burial 1, as a hypothesis to be tested. We hope the model will be considered by colleagues who study related archaeological populations, the ergonomics of living sugar cane workers, and the biomechanics of comparable behaviors.

There are several recommendations that can be addressed if archaeological excavations are expanded upon and/or acquisition of a larger sample of human remains occurs on Guana.

1. The biological model of sugar cane workers hypothesized on the basis of the present study can be tested with additional human skeletal evidence from this site. Comparative studies of skeletons of individuals under differing labor regimes could be used to further test this hypothesis..
2. Infectious disease and nutritional stress has been assessed in these two individuals that might be verified or better understood on the basis of additional archival, archaeological, and faunal evidence.
3. Evidence of stress in the observed individuals is associated with different points in their life cycles. Information about their locations in parts of Africa, North America, and the Caribbean at various ages is essential to telling their personal stories. Chemical sourcing data including both lead and strontium isotopes should reveal much about their geographical migrations.
4. It is recommended that reburial of the two individuals discussed in the current report take place in a manner deemed appropriate by descendant Tortollans. Such a reburial may be preceded by an educational forum in which the scientific knowledge about the identities of the two individuals

discussed in this report is shared with the local community. Those events could preface plans for future study and/or relocation of Guana remains should the owners of the land decide to further develop land in which the cemetery is located.

Section X Resources

Barka, N. F., E. C. Harris, and P. L. Kandle

- 1999** Guana Island Archaeological Project: The Sugar Factory (GN1) A Report on the First Season. Manuscript on file at the Department of Anthropology, College of William and Mary.

Bass, W. M.

- 1995** Human Osteology: A Laboratory and Field Manual. 4th edition. Special Publications no. 2. Missouri: Missouri Archaeological Society.

Bates, B.

- 2001** Ceramic Period Prehistoric Settlement in the Virgin Island Group, United States and British Virgin Islands. PhD Dissertation, University College London.

Blakey, M.L., Teresa E. Leslie and Joseph P. Reidy.

- 1994** Frequency and Chronological Distribution of Dental Enamel Hypoplasia in Enslaved African Americans: A Test of the Weaning Hypothesis" In American Journal of Physical Anthropology 95:371-383.

Blakey, M.L. and A. Barrett

- 2004** Analysis of Two Human Skeletons from Smith's Fort, Bermuda. Bermuda Journal of Archaeology and Maritime History 15: 48 – 69.

Brooks, S.T. and J.M. Suchey

- 1990** Skeletal Age Determination Based on the Os Pubis: A Comparison of the Acsadi-Nemeskeri and Suchey-Brooks Methods. Human Evolution 5:227-238.

Brothwell, D.R.

- 1963** Dental Anthropology. New York: MacMillan.

Buikstra, J.E. and D.H. Ubelaker, eds.

- 1994** Standards: For Data Collection From Human Skeletons. Arkansas Archaeological Survey Research Series No. 44. Arkansas.

Bush, B.

- 1990** Slave Women in Caribbean Society: 1650 - 1838. Indianapolis: Indiana University Press.

Capasso, L., K. Kennedy and C. Wilczak

- 1999** Atlas of Occupational Markers on Human Remains. Italy: Edigrafital SpA.

- Clement, C. O.
 1995 Landscapes and Plantations on Tobago: A Regional Perspective. PhD Dissertation, University of Florida.
- Diderot, Denis
 1993 A Diderot Pictorial Encyclopedia of Trades and Industry: Manufacturing and the Technical Arts in Plates Selected from "L'Encyclopédie, ou dictionnaire Raisonné des Sciences, des Arts et des Métiers" of Denis Diderot. Edited and with an introduction and Notes by Charles C. Gillispie. Volume 1, Plate II, figure 1 and Plate IV [1762].
- Dookhan, I.
 1975 A History of the British Virgin Islands 1672 to 1970. Essex, England: Caribbean Universities Press.
- Drezner, M.K
 1995 Osteoporosis types I and II. In Calcium and Phosphorus in Health and Disease, ed. J.J.B. Anderson & S.C. Garner, pp. 341-54. Boca Raton: CRC Press.
- Dunn, R. S.
 1973 [1972] Sugar and Slaves: The Rise of the Planter Class in the English West Indies, 1624-1713. New York: W.W. Norton & Company.
- Goodman, A.H., A.J. Armelagos, and R.C. Rose.
 1980 Enamel Hypoplasias as indicators of stress in three prehistoric populations from Illinois. Human Biology 52:515-528.
- Goodwin, C. M.
 1987 Sugar, Time, and Englishmen: A Study of Management Strategies on Caribbean Plantations. PhD Dissertation, Boston University.
- Goveia, E.V.
 1965 Slave Society in the British Leeward Islands at the End of the Eighteenth Century. London: Yale University Press.
- Handler, J.S. and R. S. Corruccini
 1983 Plantation Slave Life in Barbados: A Physical Anthropological Analysis. Journal of Interdisciplinary History XIV (I): 65-90.
- Hutchinson, D.L., C.B. Denise, H.J. Daniel, and G.W.Kalmus
 1997 A Reevaluation of the Cold Water Etiology of External Auditory Exostoses. American Journal of Physical Anthropology 103:417-422.
- Iskan, M.Y., S.R.Loht and R.K. Wright
 1984 "Age estimation from the ribs by phase analysis: white males" Journal of Forensic Sciences 30: 853-863.

- Jenkins, C.
1923 *Tortola: A Quaker Experiment of Long Ago in the Tropics*. London: Friends Bookshop.
- Kostro, M.
2004 "Guana Island Archaeological Project: Preliminary Burial Report and Skeletal Inventory." Manuscript on file at the Institute for Historical Biology, Department of Anthropology, College of William and Mary.
- Kostro, M., E. C. Harris, N. F. Barka, and M. R. Brown III
2005 850-acres, 25 archaeological sites, 4 archaeologists, 1 island: A report on the Guana Island Archaeological Project. Paper presented at the Annual Meeting of the Society for Post Medieval Archaeology, Nevis, W.I.
- Larsen, C.S.
2000 *Bioarchaeology: Interpreting Behavior From the Human Skeleton*. Cambridge: Cambridge University Press.
- Lewisohn, F.
1966 *Tales of Tortola and the British Virgin Islands*. Hollywood, Florida: Dukane Press.
- Lovejoy, C. O., R.S. Meindl, T.R. Pryzbeck, and R.P. Mensforth
1985 Chronological Metamorphosis of the Auricular Surface of the Ilium: A New Method for the Determination of Age at Death. *American Journal of Physical Anthropology* 68:15-28.
- McGlynn, F.
1980 *Marginality and Flux: An Afro-Caribbean Community through Two Centuries*. PhD Dissertation, University of Pittsburgh.
- McKern, T. and T.D. Stewart
1957 *Skeletal Age Changes in Young American Males, Analyzed from the Standpoint of Identification*. Technical Report EP-45. Headquarters, Quartermaster Research and Development Command, Natick, Massachusetts
- Mintz, S.M.
1960 *Worker in the Cane: A Puerto Rican Life History*. London: Yale University Press.
- Moitt, B.
2004 *Sugar, Slavery and Society: Perspectives on the Caribbean, India, the Mascarenes, and the United States*. Florida: University Press of Florida.

- Maat, G.J.R.
 2004 Scurvy in Adults and Youngsters: the Dutch Experience. A Review of the History and Pathology of a Disregarded Disease. *International Journal of Osteoarchaeology* 14:77-81.
- Melkian, M. and T. Waldron
 2002 An Examination of Skulls from Two British Sites for Possible Evidence of Scurvy. *International Journal of Osteoarchaeology* 13:207-212.
- Mintz, Sydney W.
 1960 *Worker in the Cane: A Puerto Rican Life History*. New Haven: Yale University Press. Figures 12, 13 and 14.
- Ortner, D. J., W. Butler, J. Cafarella, and L. Milligan
 2001 Evidence of Probable Scurvy in Subadults From Archaeological Sites in North America. *American Journal of Physical Anthropology* 114:343-351.
- Ortner, D.J., M.F. Ericksen
 1997 Bone Changes in the Human Skull Probably Resulting from Scurvy in Infancy and Childhood. *International Journal of Osteoarchaeology*. 7:212-220.
- Ortner, D.J., E.H. Kimmerle, and M. Diez
 1999 Probable Evidence of Scurvy in Subadults From Archeological Sites in Peru. *American Journal of Physical Anthropology*. 108:321-331.
- Ortner, D.J. and W.G.J. Putschar
 1985[1981] *Identification of Pathological Conditions In Human Skeletal Remains*. Washington, D.C.: Smithsonian Institution Press.
- Pittman, William
 2005 Personal Communication.
- Rankin-Hill, L.M.
 1997 *A Biohistory of 19th-Century Afro-Americans: The Burial Remains of a Philadelphia Cemetery*. Connecticut: Bergin & Garvey.
- Righter, E.
 2003 *The Tutu Archaeological Village Site: A Multidisciplinary Case Study in Human Adaptation*. New York: Routledge.
- Stedman, J.G.
 1992(1796) *Stedman's Surinam: Life in an Eighteenth Century Slave Society*. R. Price and S. Price eds. Baltimore: John Hopkins University Press.

Trotter, M., and G.C. Gleser

**1952 Estimation of stature from long bones of American whites and Negroes.
American Journal of Physical Anthropology 16: 79-123.**

White, T. D.

2001 Human Osteology, Second Edition. San Diego: Academic Press.

Wilkinson, A.

1988 Big Sugar: Seasons in The Cane Fields of Florida. New York: Alfred Knopf.

Williams, P., ed.

1995 Gray's Anatomy, Thirty-Eighth Edition. London: Churchill Livingstone.